

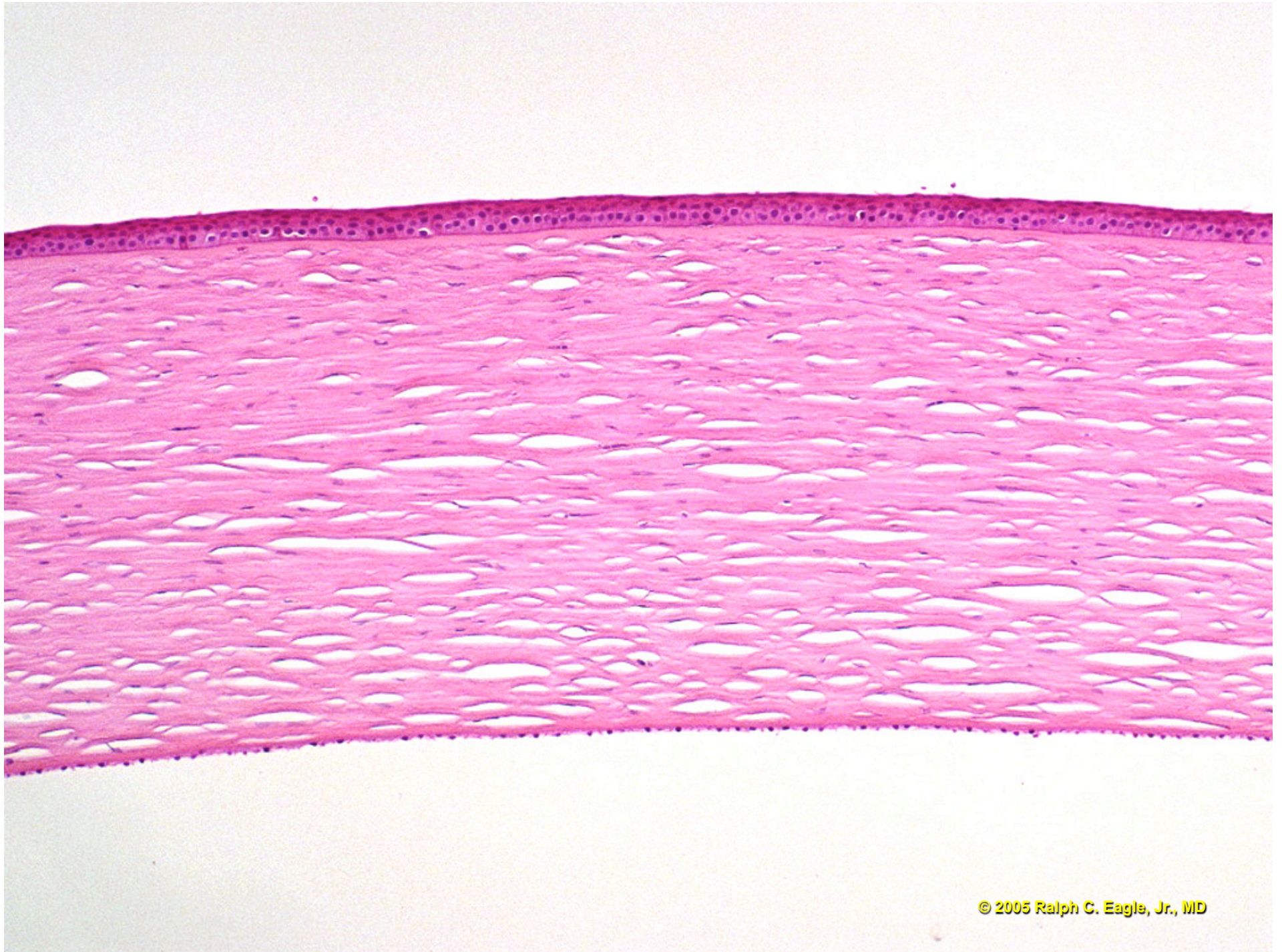
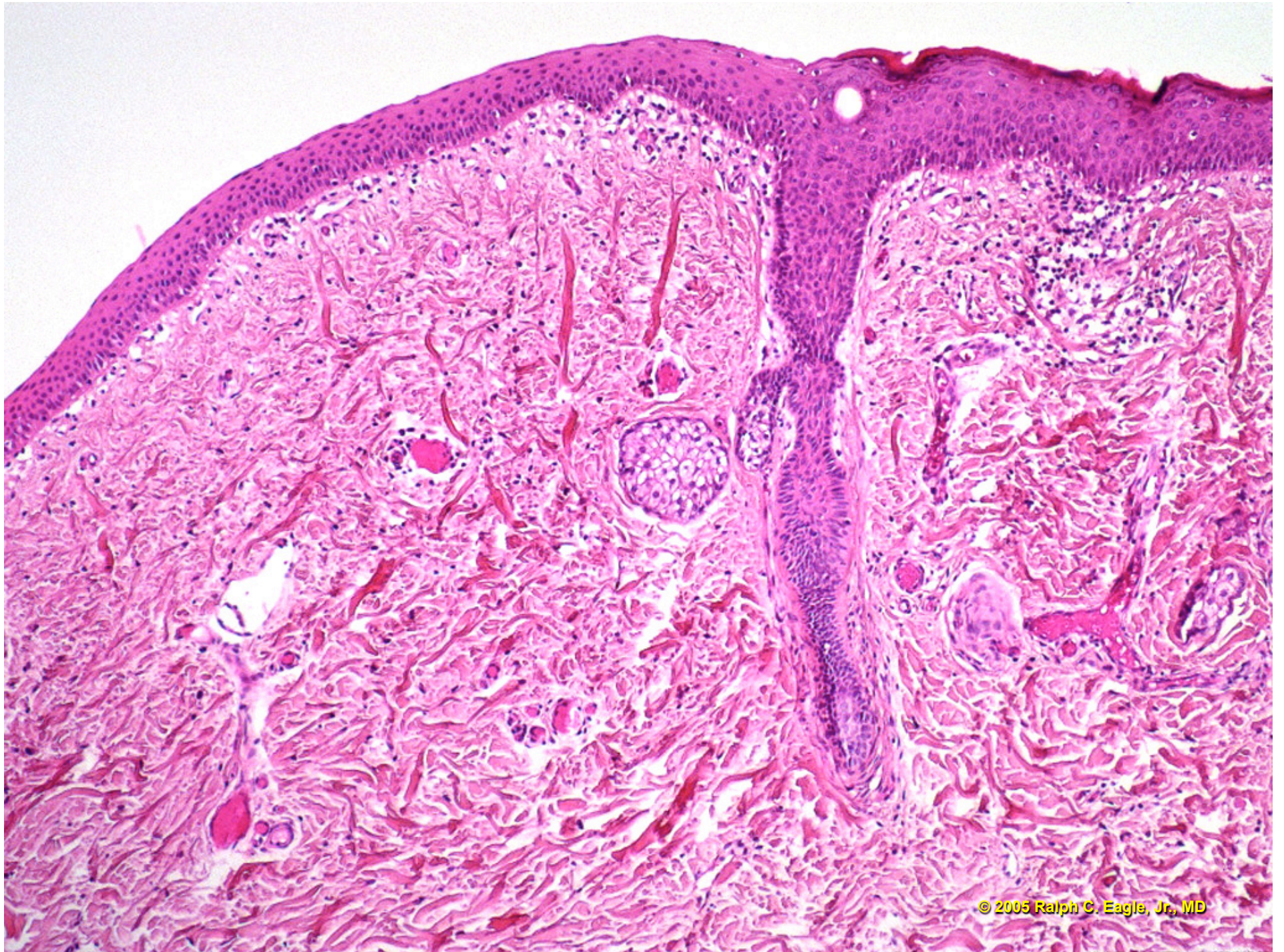

# **Histopathology of the Cornea: An Illustrative Summary**

**© 2008 Ralph C. Eagle, Jr., MD  
Department of Pathology  
Wills Eye Institute**

A histological micrograph of the cornea, stained with hematoxylin and eosin (H&E). The image shows the characteristic layered structure of the cornea. At the top is the thin, multi-layered epithelium. Below it is the thick, highly organized stroma, which is composed of numerous layers of collagen fibers and keratocytes, giving it a honeycomb-like appearance. At the bottom is the thin, single-layered endothelium. The word "cornea" is overlaid in large, bold, black lowercase letters in the center of the image.

# cornea

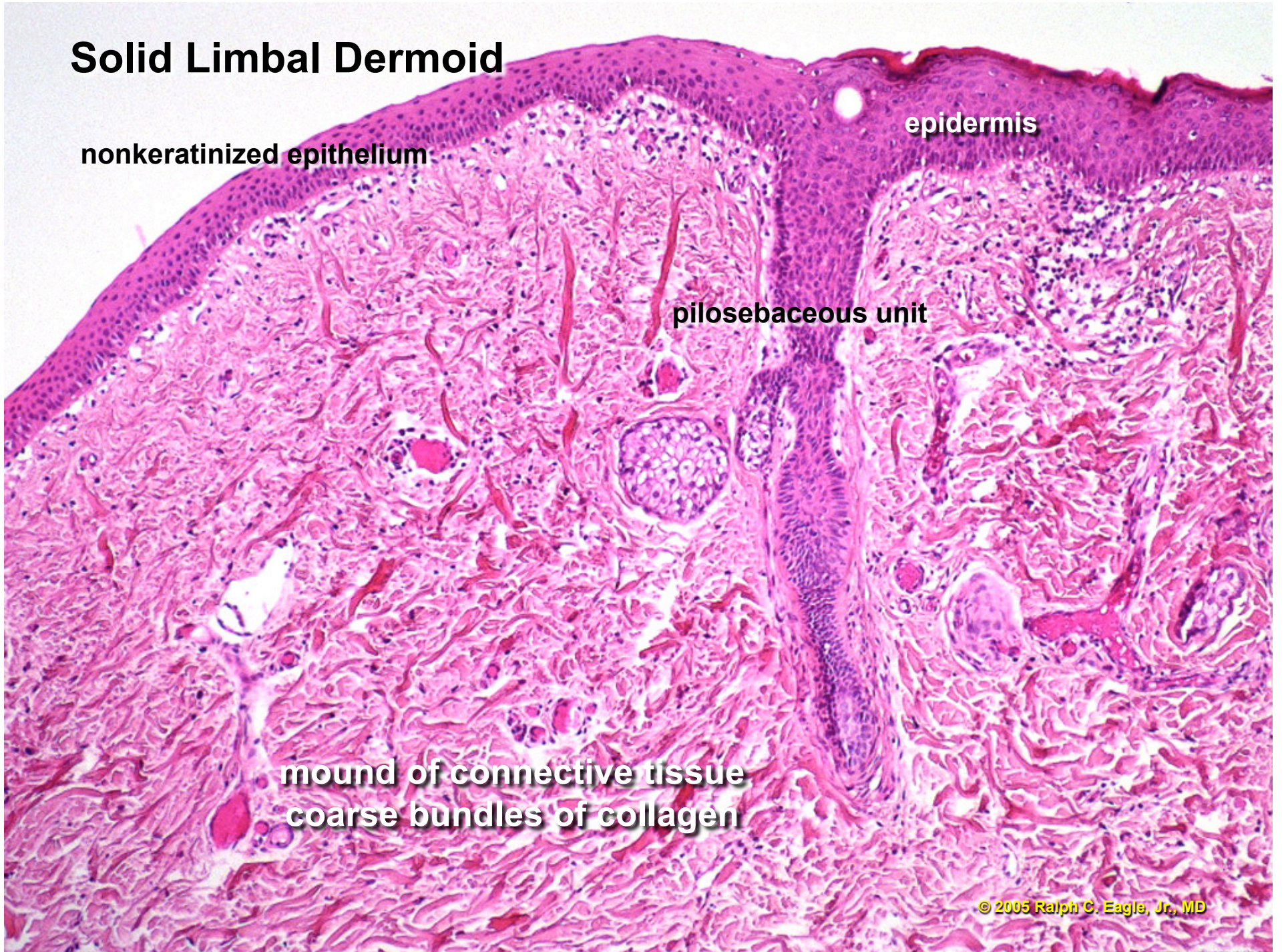




## **Solid Limbal Dermoid**

Mound of connective tissue (coarse interweaving bundles of collagen)  
Covered by skin-like epithelium with epidermal appendages  
(cartilage, fat, and/or lacrimal gland  
in *complex choristoma*)

# Solid Limbal Dermoid

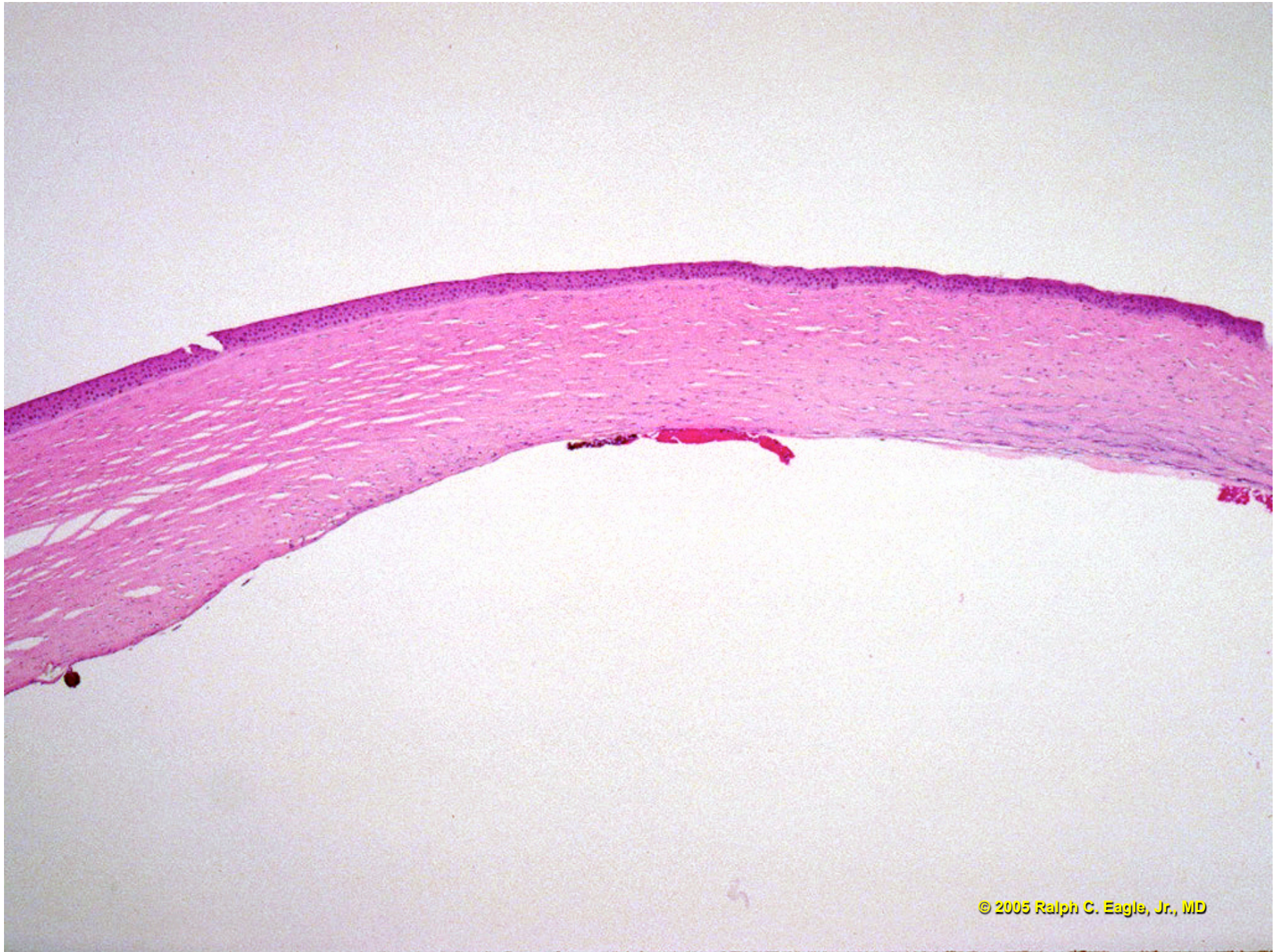

nonkeratinized epithelium

epidermis

pilosebaceous unit

mound of connective tissue  
coarse bundles of collagen

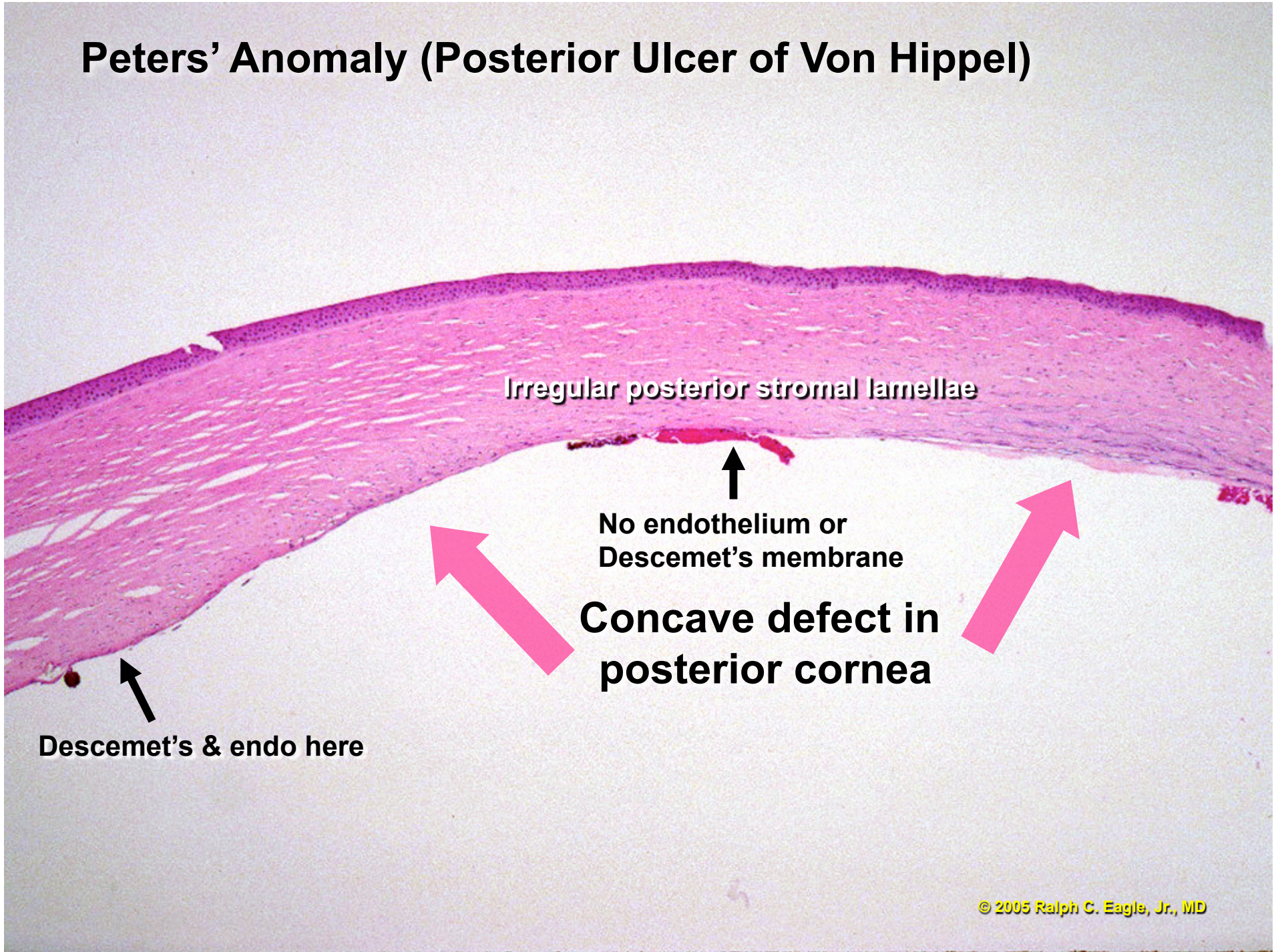


# **Peters' Anomaly**

## **(Posterior Ulcer of Von Hippel)**

Central concave focus of posterior corneal stromal loss  
Endothelium and Descemet's membrane absent in "ulcer"  
Adjacent stromal lamellae thick and disorderly  
(Posterior ulcer plus kerato-lenticular and iridocorneal  
adhesions in Peters' Anomaly)

# Peters' Anomaly (Posterior Ulcer of Von Hippel)

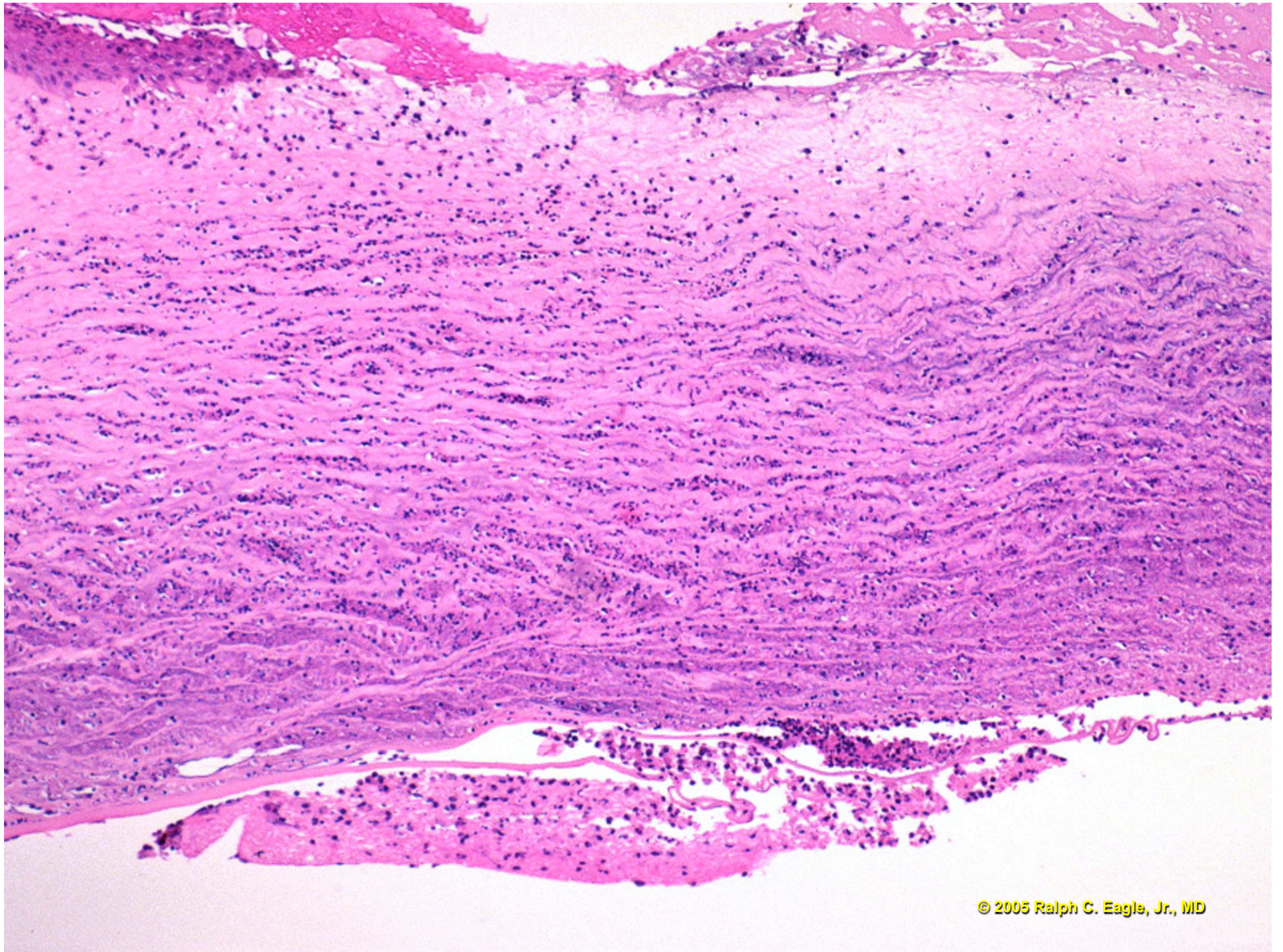


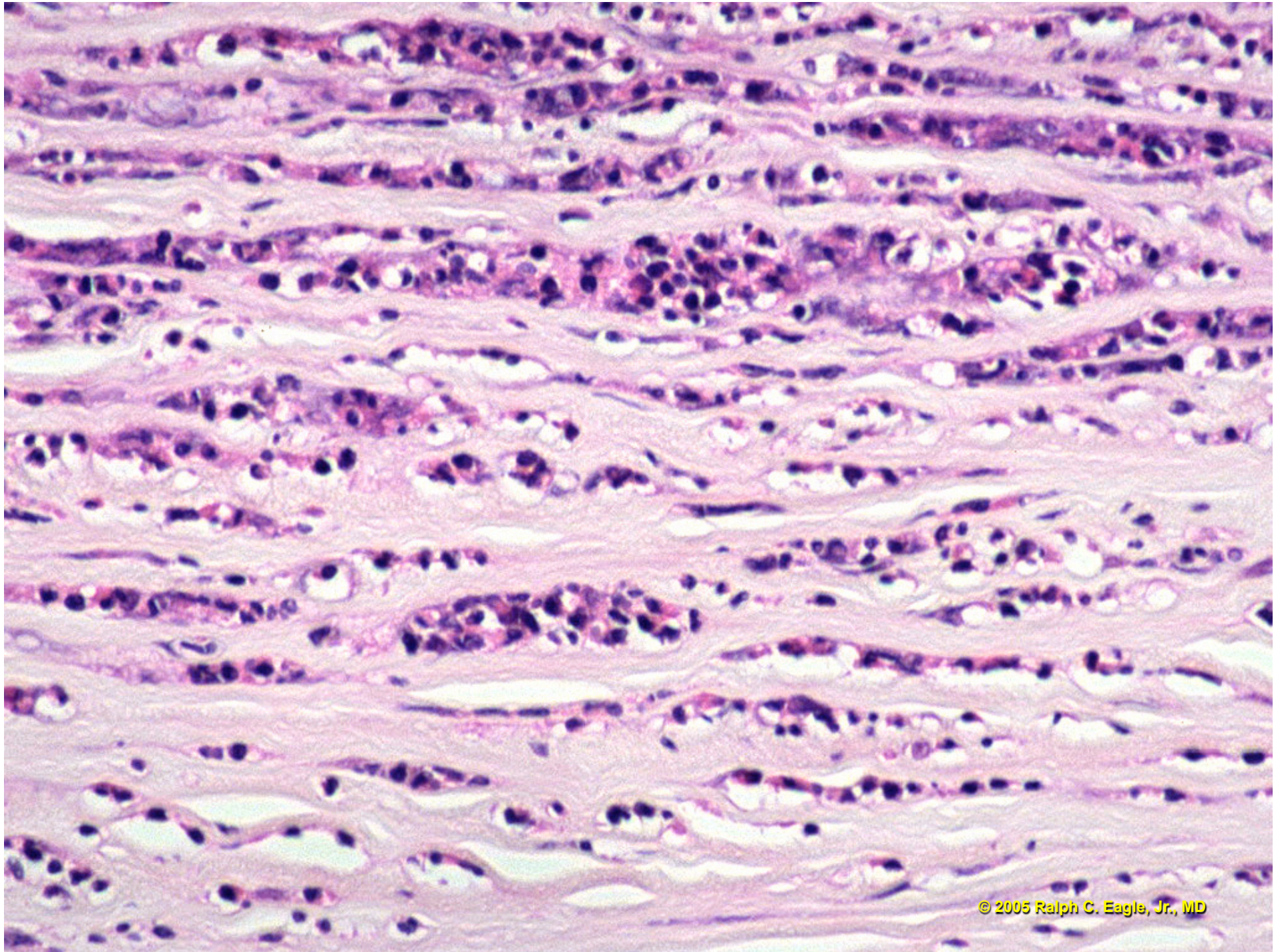
Irregular posterior stromal lamellae

No endothelium or  
Descemet's membrane

Concave defect in  
posterior cornea

Descemet's & endo here





# Acute Keratitis

Loss of epithelium, Bowman's and anterior stroma (ulcer)

Polys and necrotic debris in interlammelar clefts

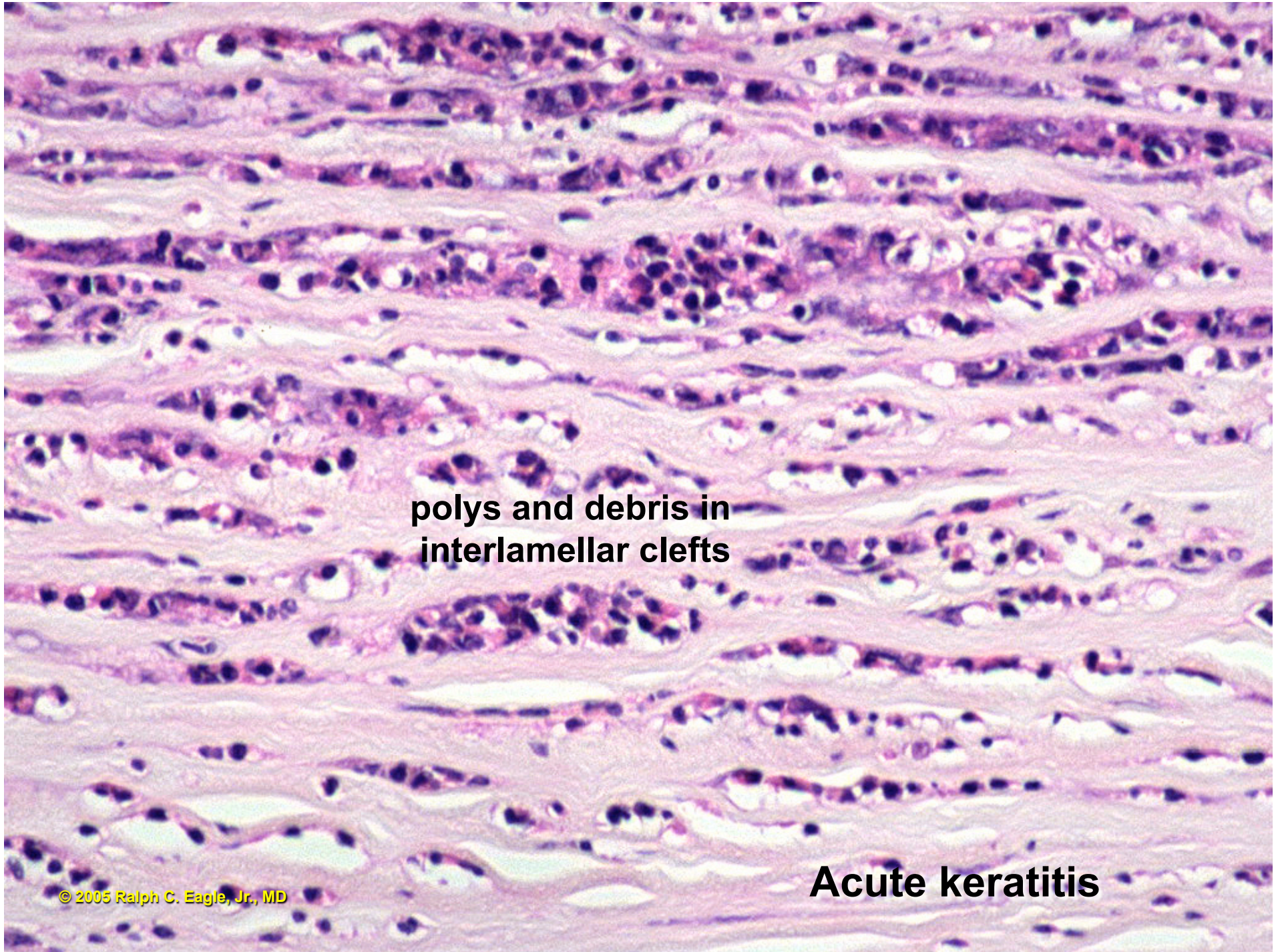
Fungal hyphae may be deep

Infectious crystalline keratopathy- large interlammelar  
bacterial colonies in non inflamed stroma

A histological micrograph of a corneal section stained with hematoxylin and eosin (H&E). The image shows a dense, polymorphous infiltrate of inflammatory cells within the stroma, extending from the epithelial layer. There is evidence of necrosis in the tissue. The epithelium at the top is partially detached and shows signs of damage. The overall appearance is characteristic of acute keratitis.

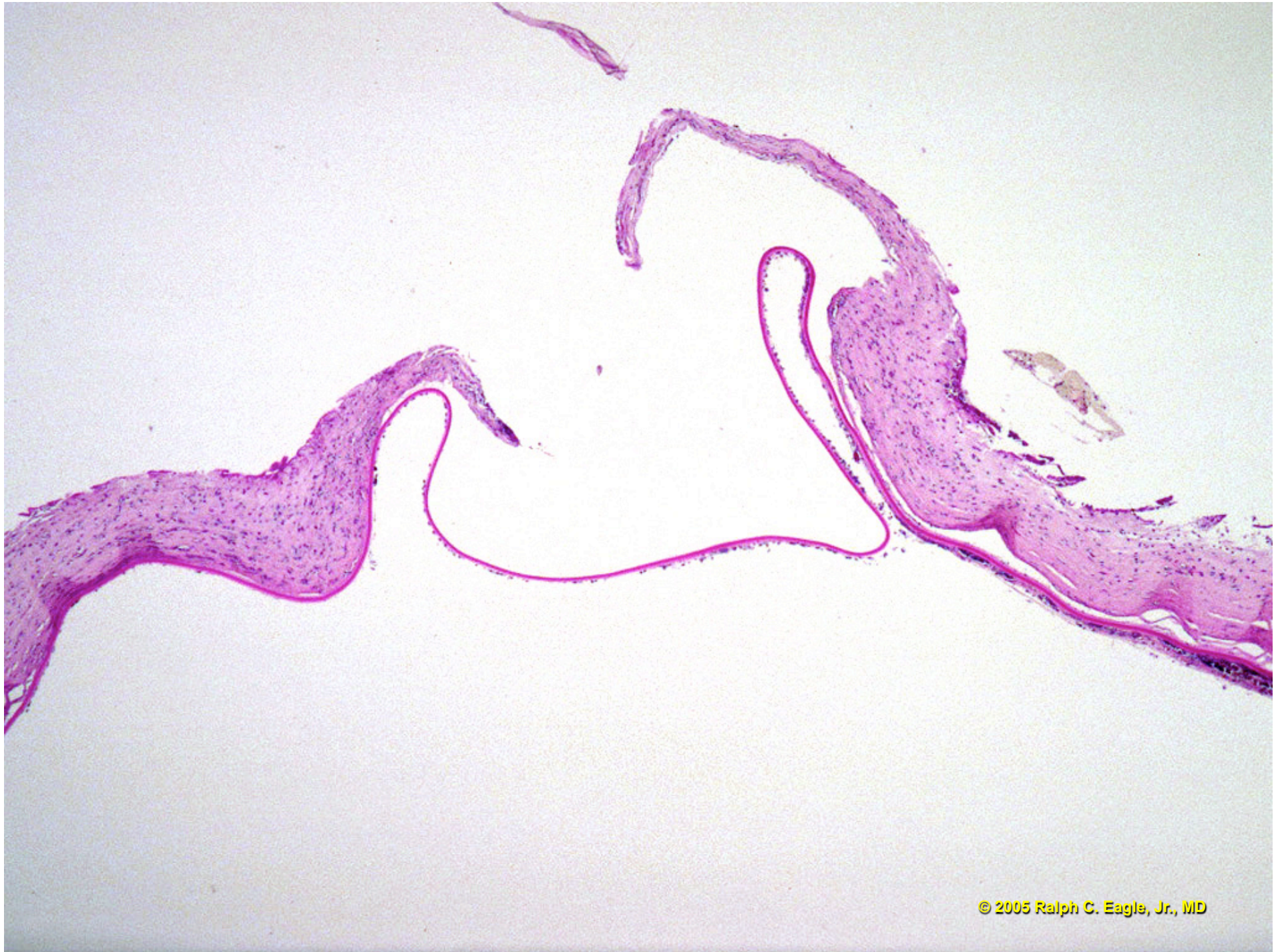**polys and necrosis**

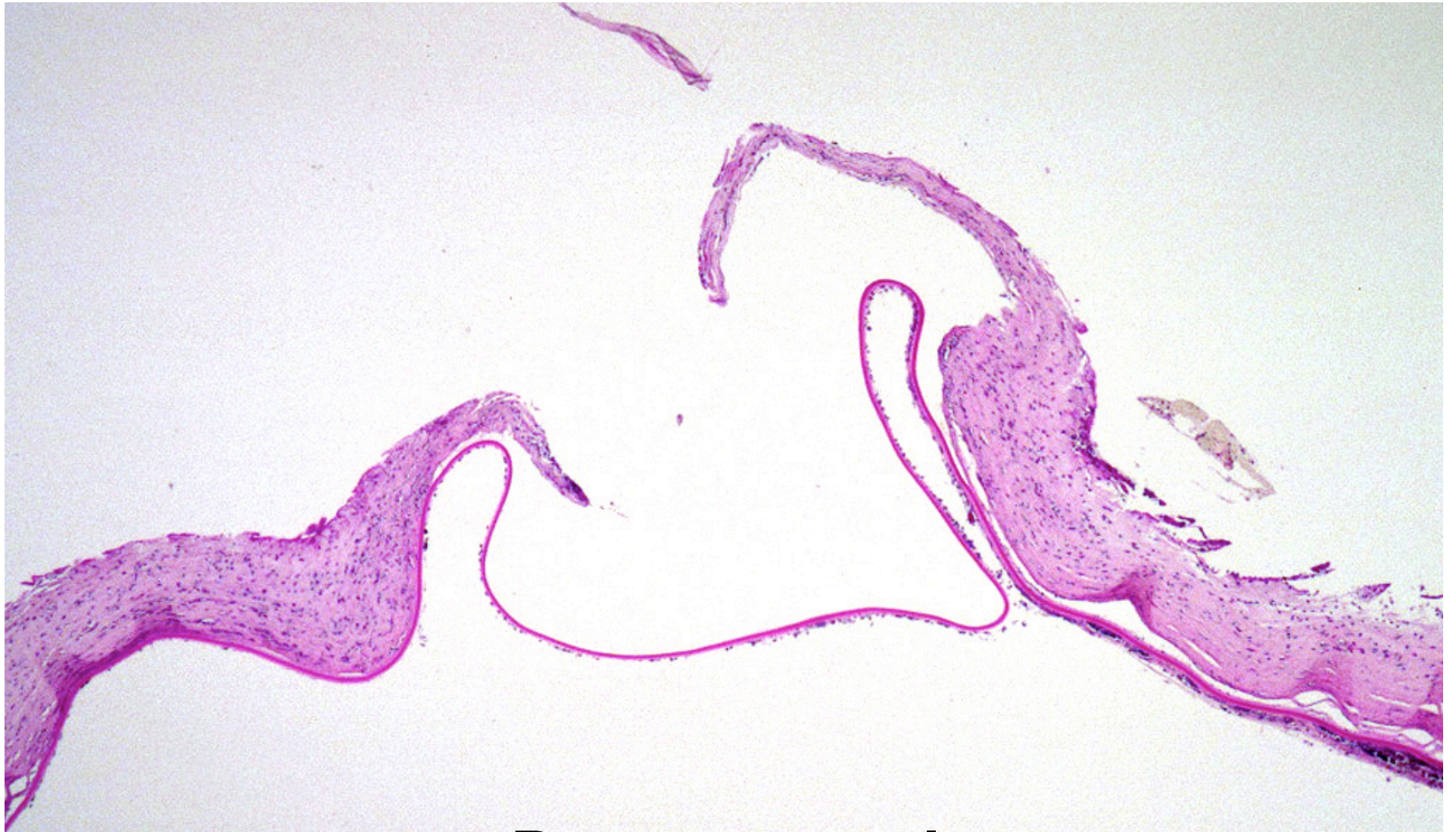**Acute keratitis**



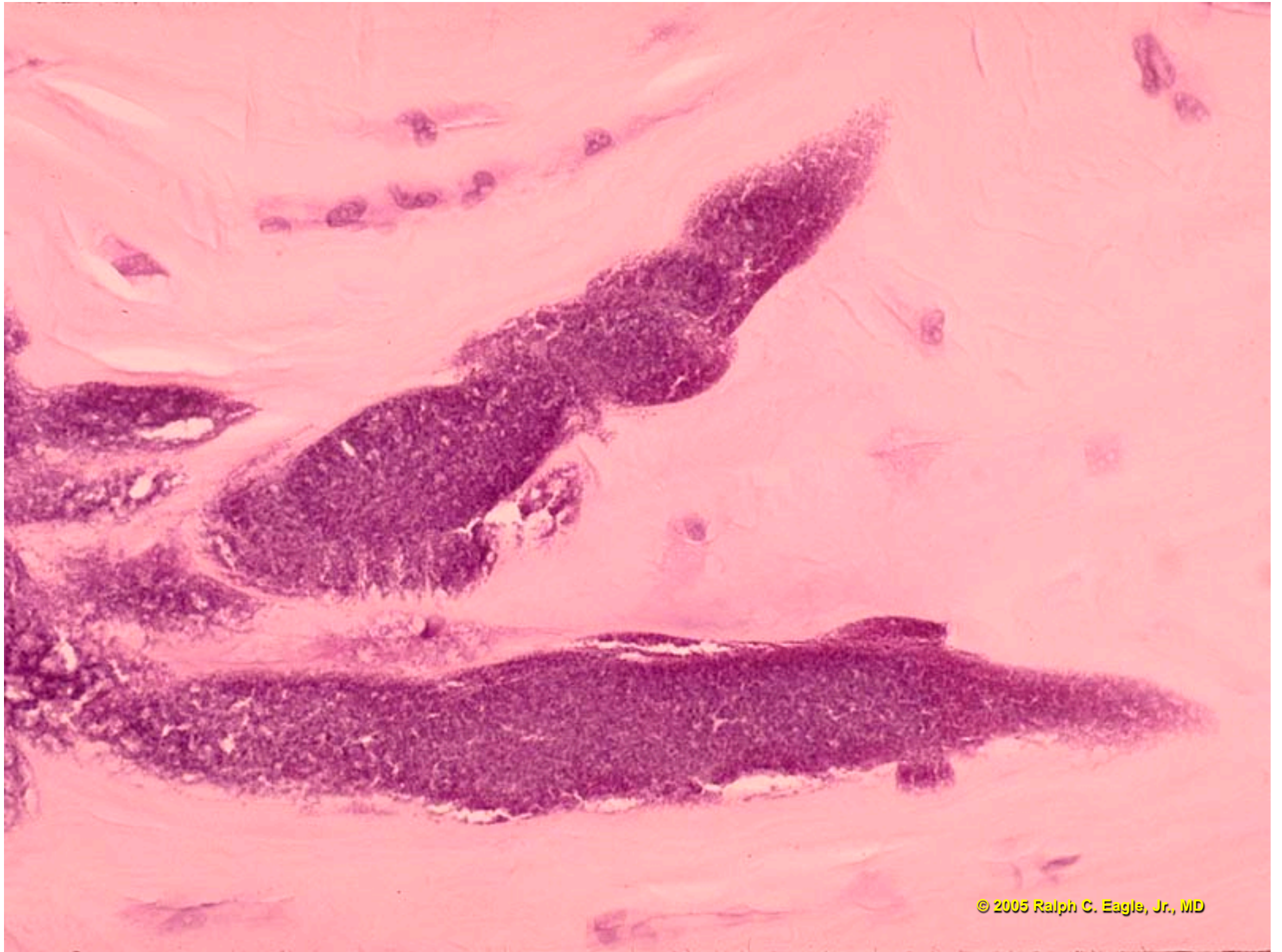
**polys and debris in  
interlamellar clefts**

**Acute keratitis**





# Descemetocoele



# **Infectious Pseudocrystalline Keratopathy**

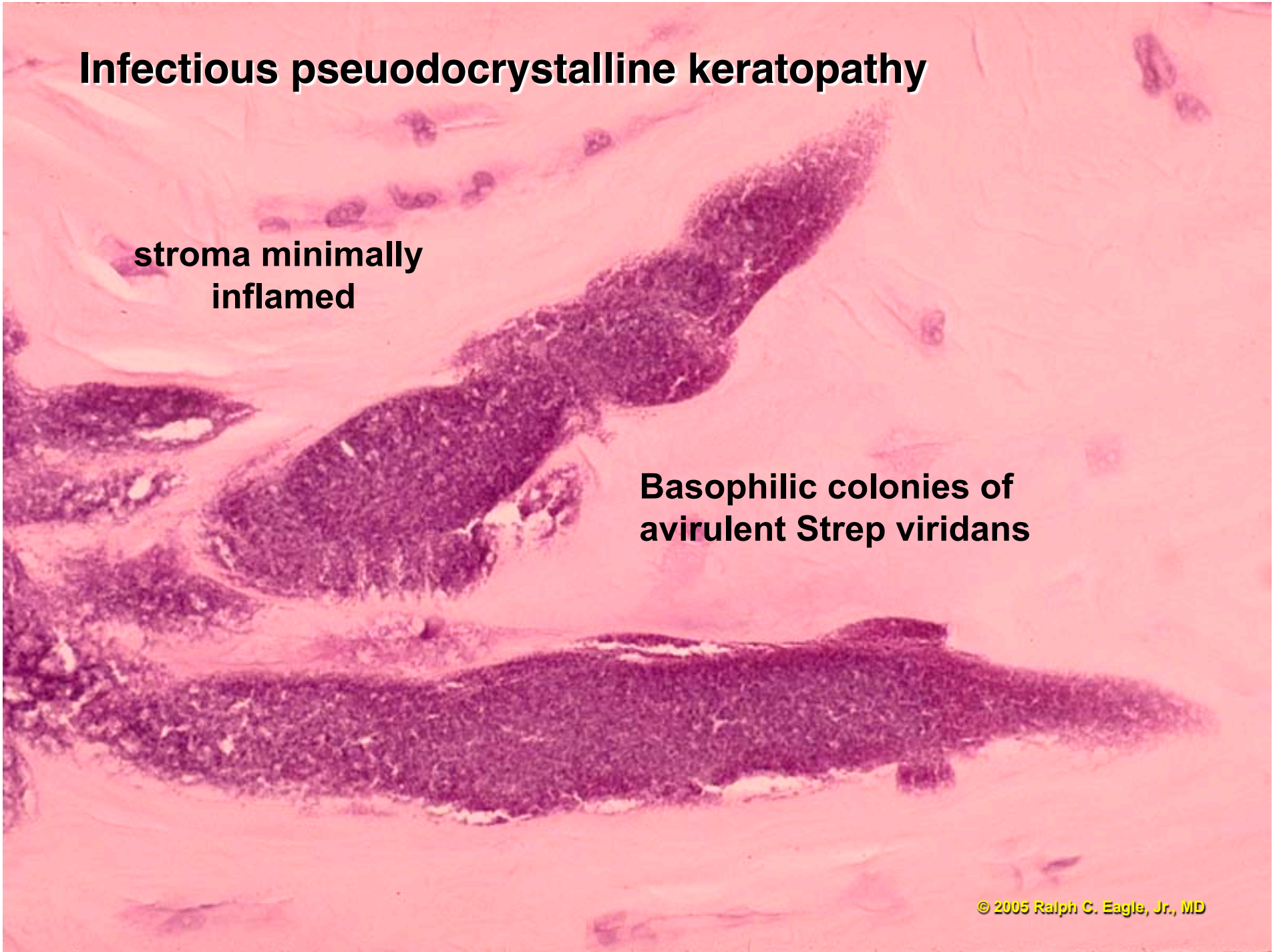
Large basophilic interlamellar colonies of avirulent Streptococci sequestered by glycocalyx in non-inflamed stroma

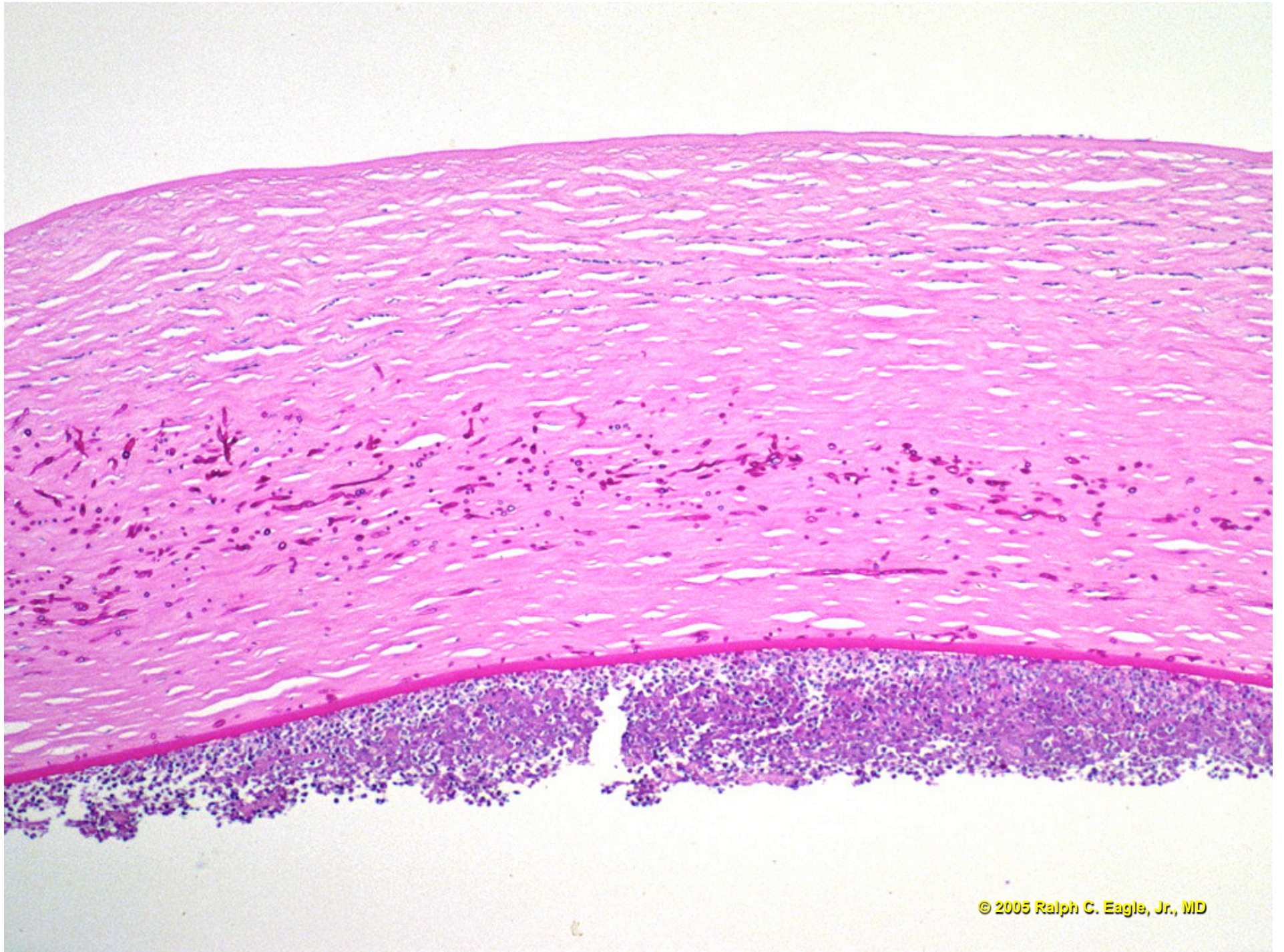
History of chronic steroid therapy

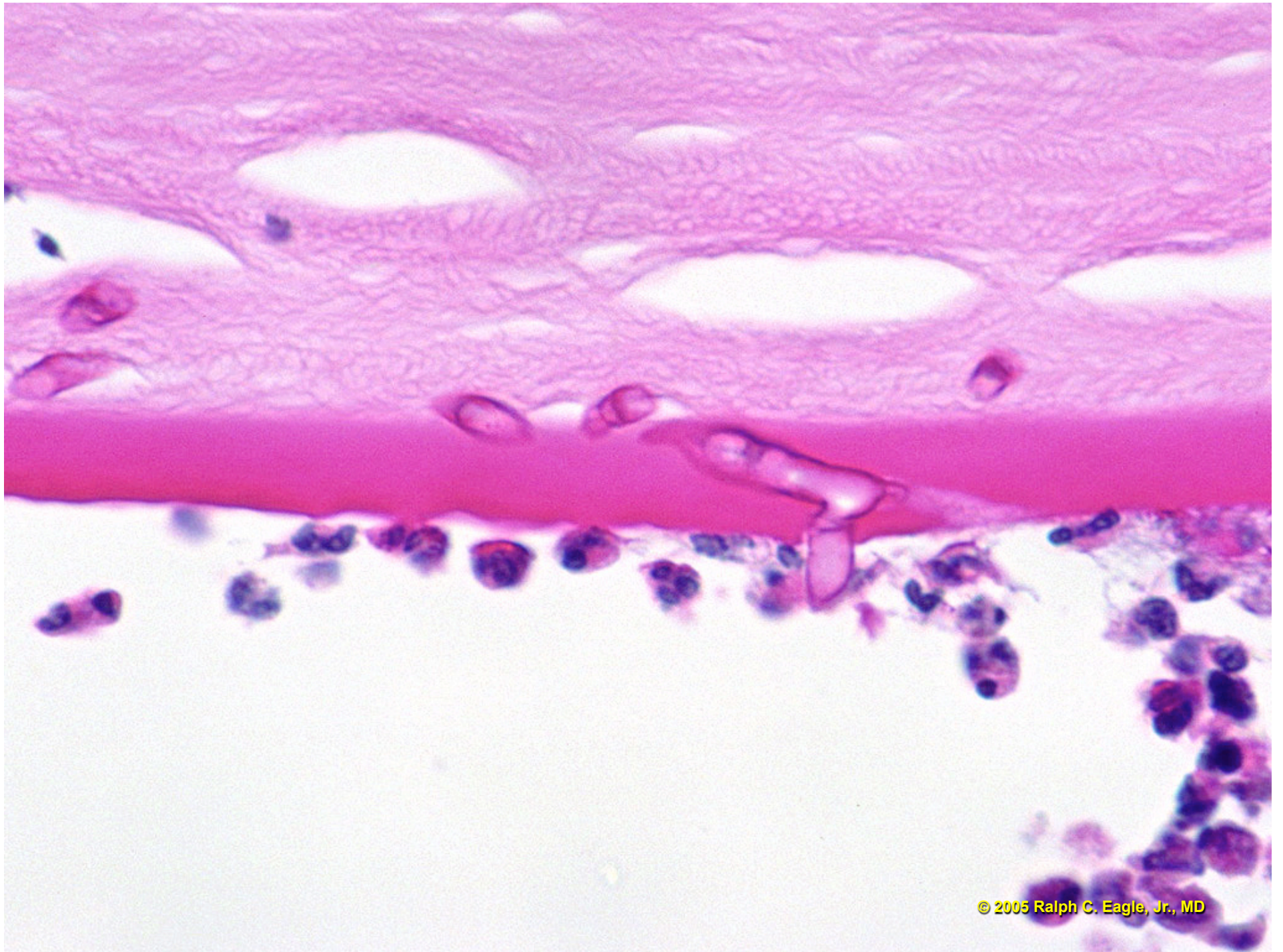
# Infectious pseudocrystalline keratopathy

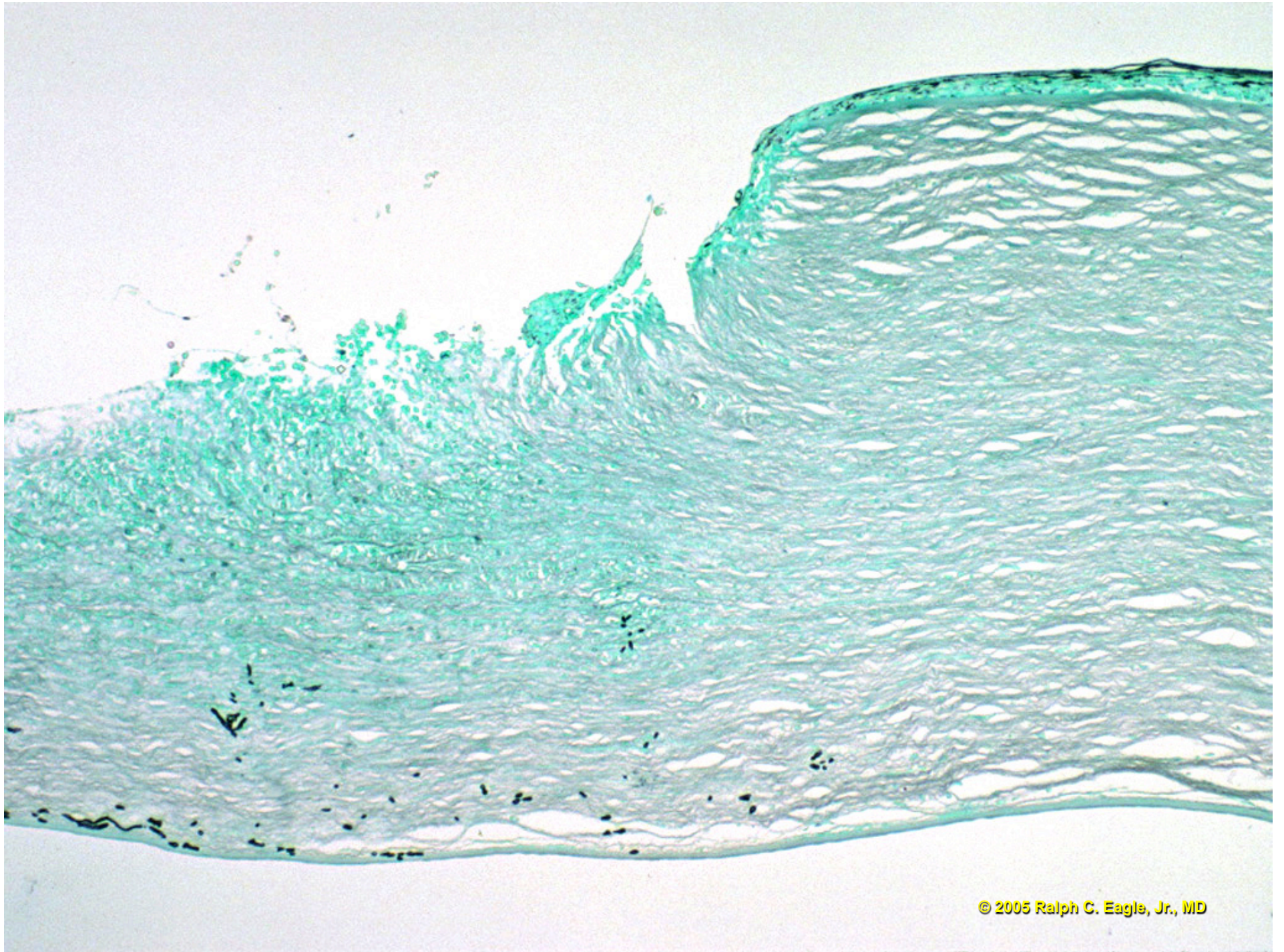
stroma minimally  
inflamed

Basophilic colonies of  
avirulent *Strep viridans*







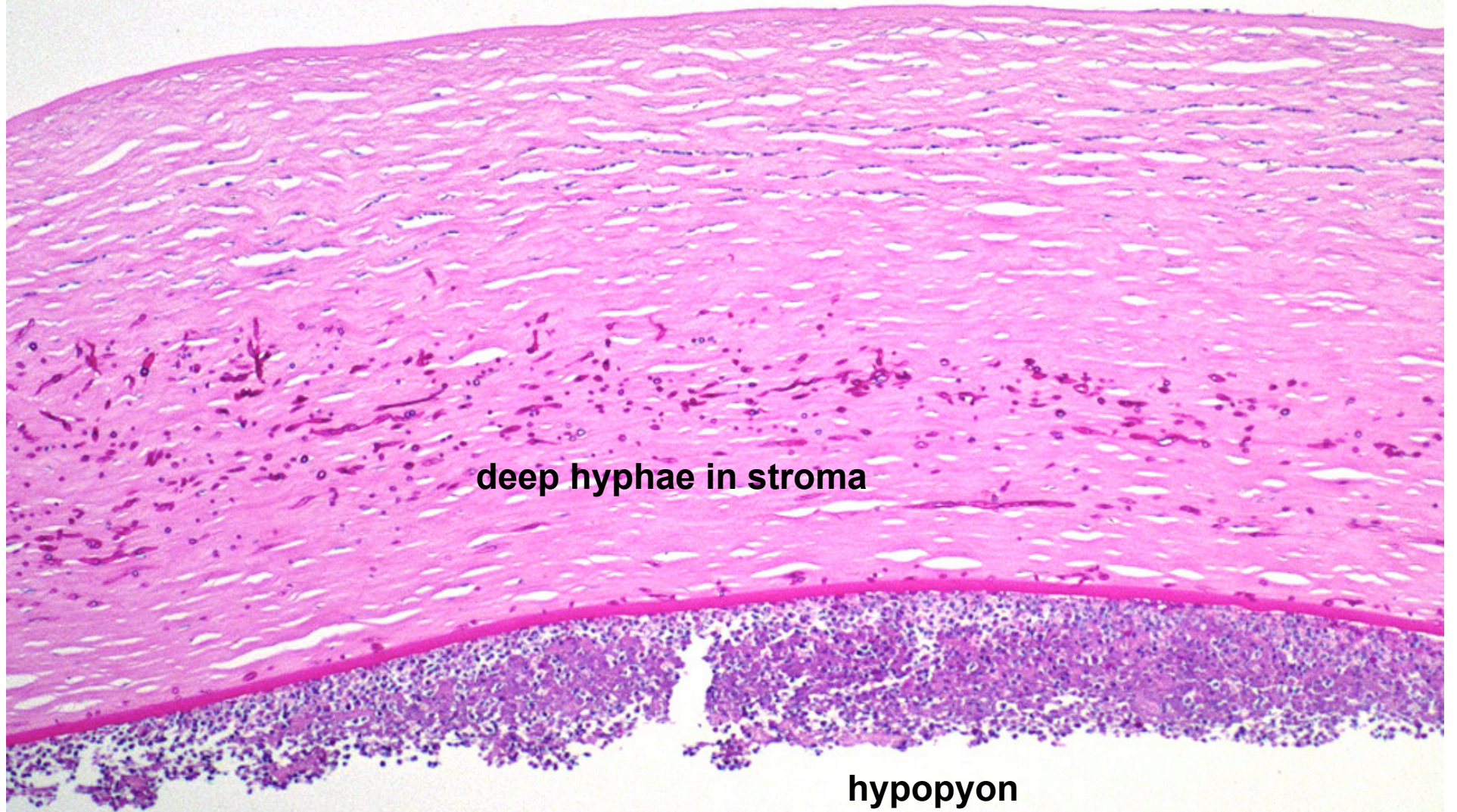


# **Fungal keratitis**

Fungal hyphae may be deep  
requiring biopsy for diagnosis

PAS or GMS stains

# **fungal keratitis**



**deep hyphae in stroma**

**hypopyon**

**PAS stain**

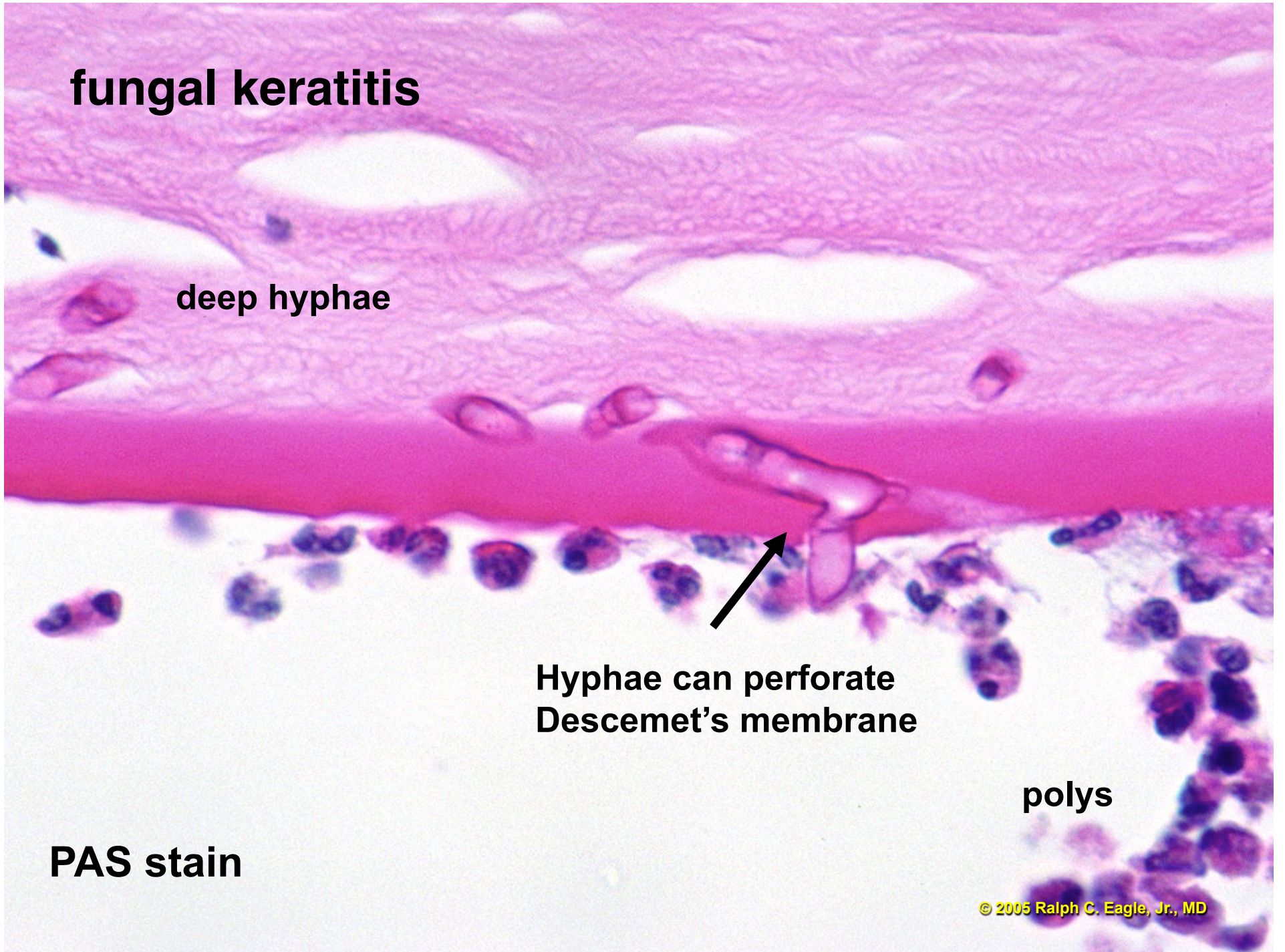
**fungal keratitis**

**deep hyphae**

**Hyphae can perforate  
Descemet's membrane**

**polys**

**PAS stain**



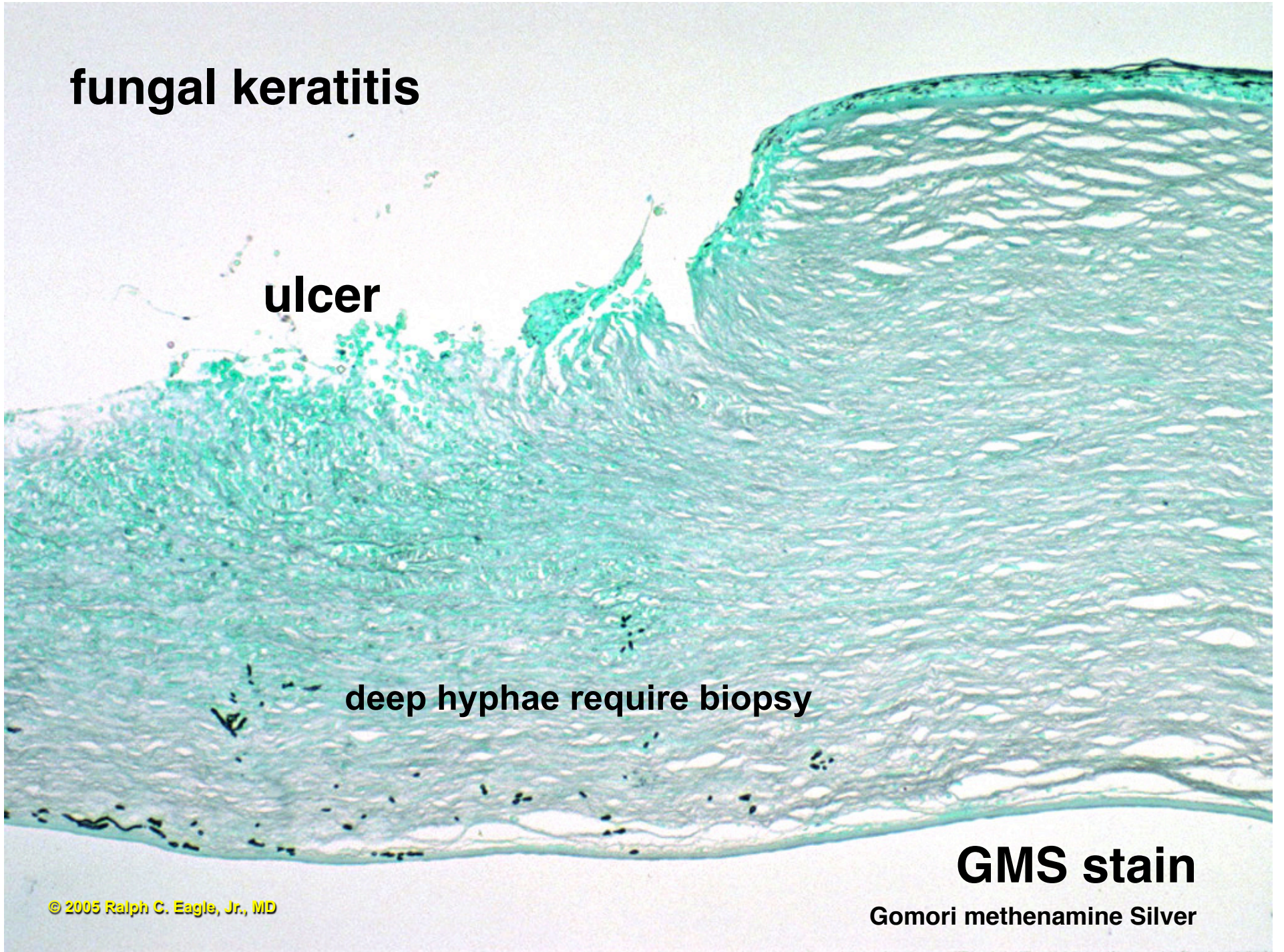
**fungal keratitis**

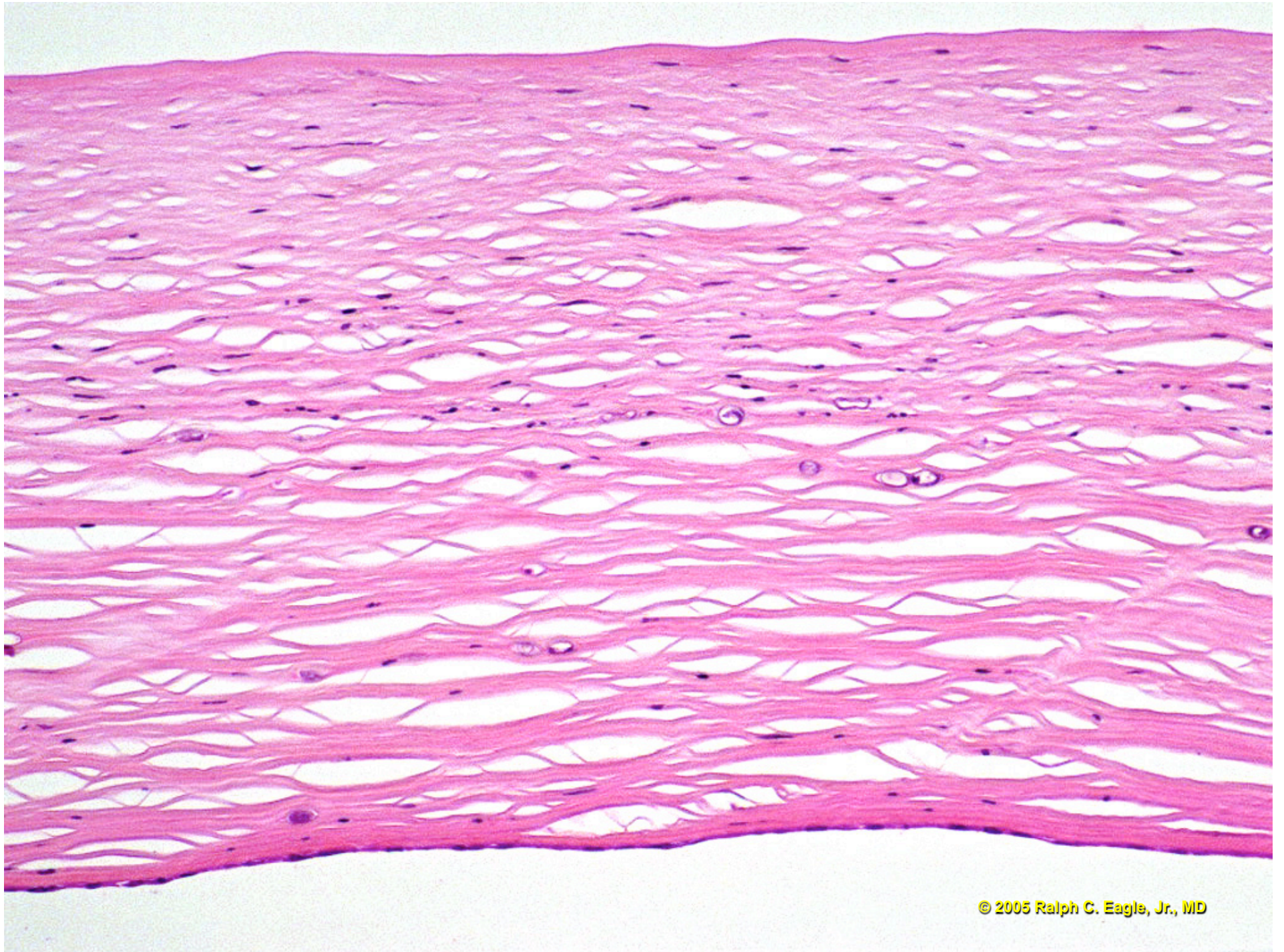
**ulcer**

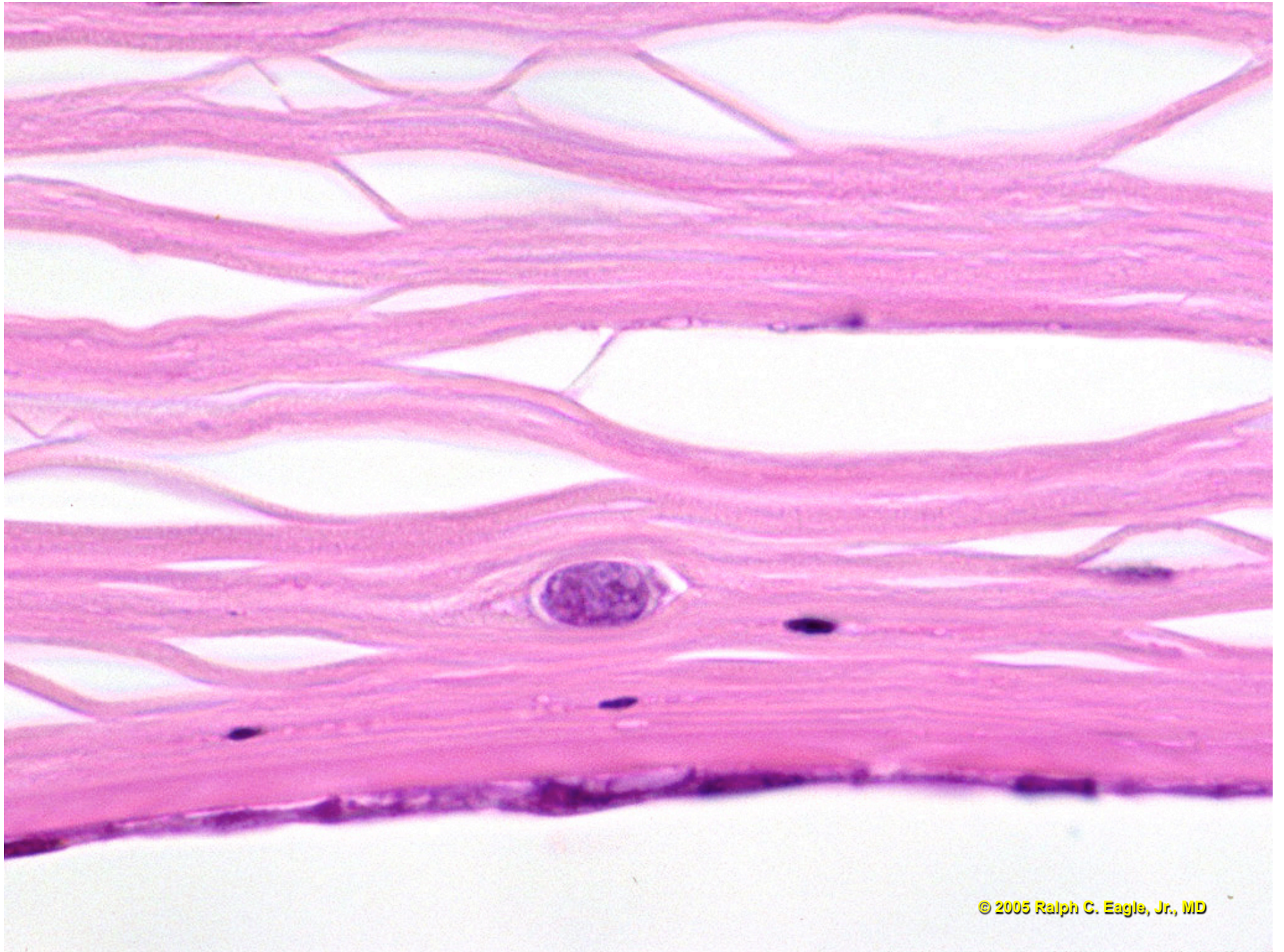**deep hyphae require biopsy**

**GMS stain**

Gomori methenamine Silver







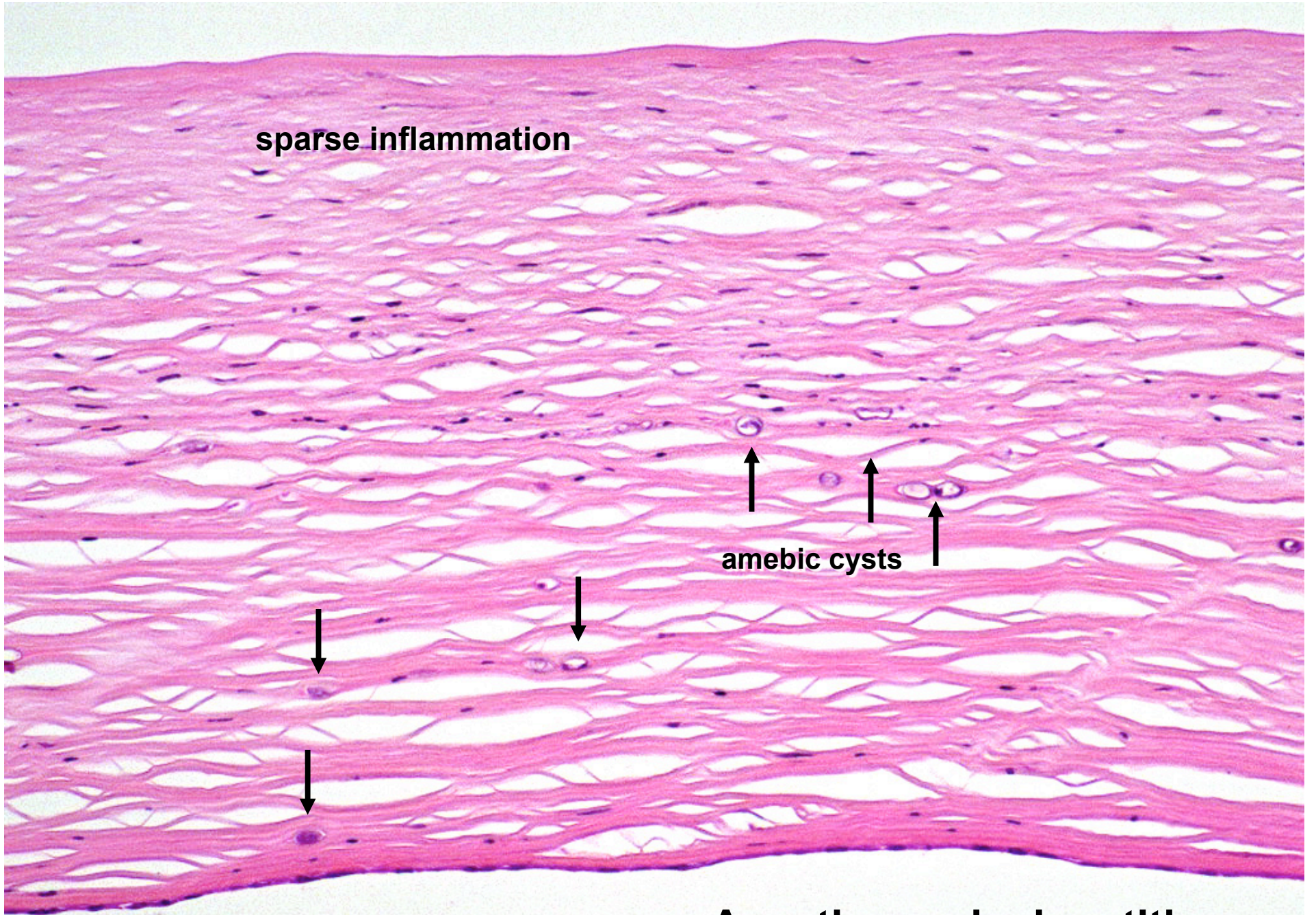
# **Acanthamoeba Keratitis**

Epithelium absent, Bowman's membrane intact,  
only mild necrosis

Inflammation relatively sparse (compared to  
fungal or bacterial keratitis)

Oval amoebic cysts in stroma (round nucleus  
with nucleolus, cytoplasm shrinks and pulls  
away from cyst wall)

Trophozoites resemble macrophages, difficult to  
identify



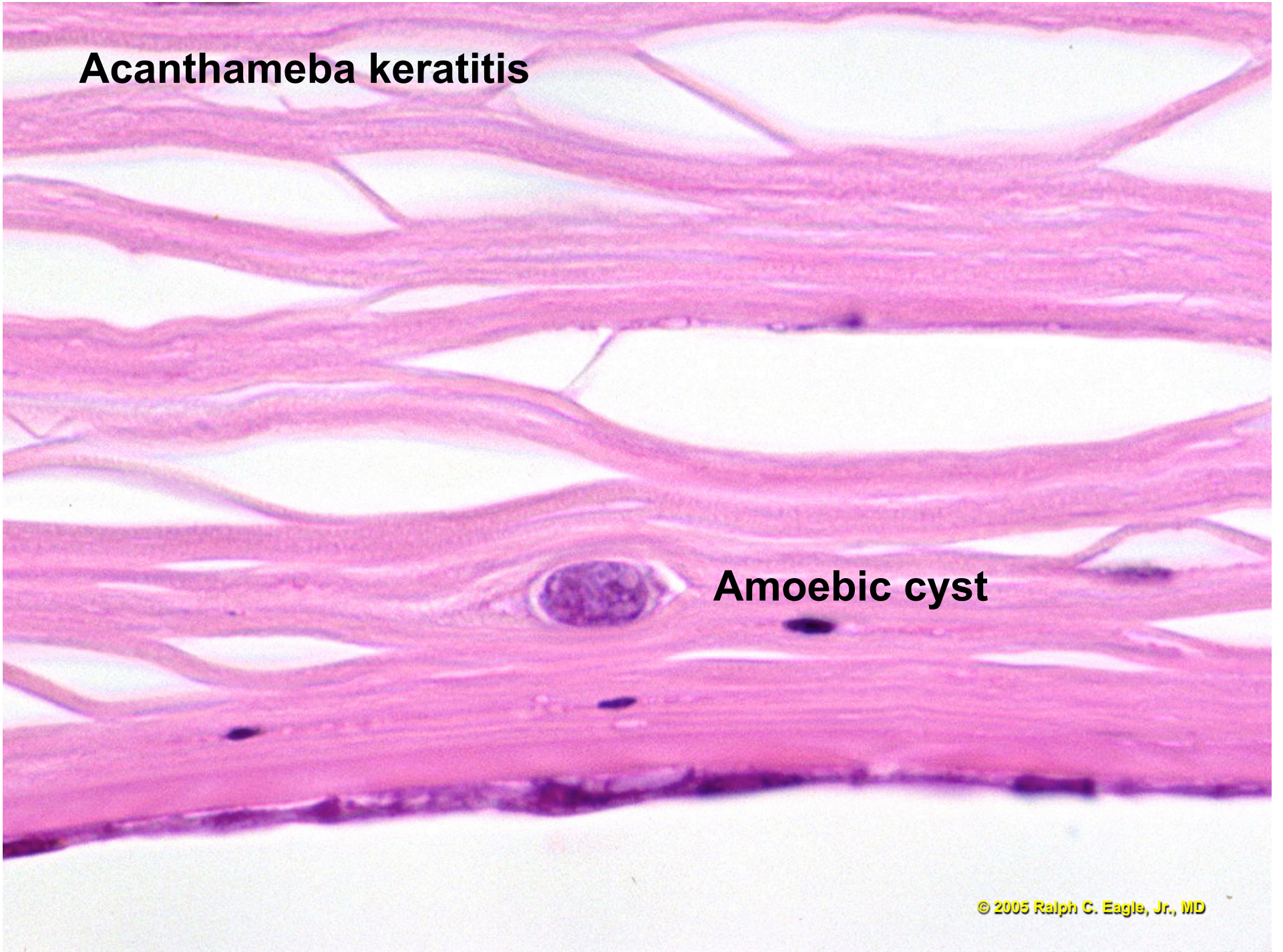
sparse inflammation

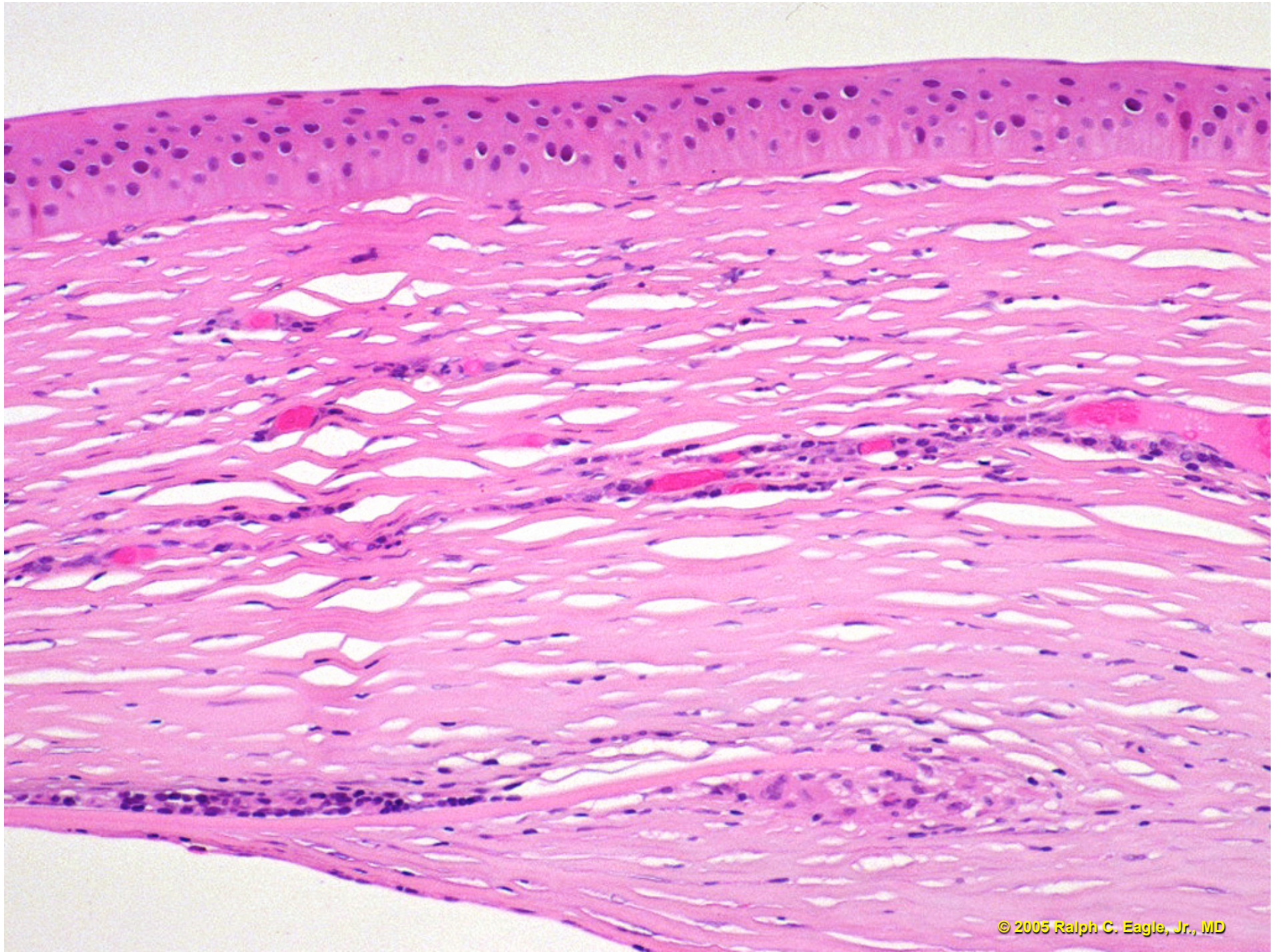
amebic cysts

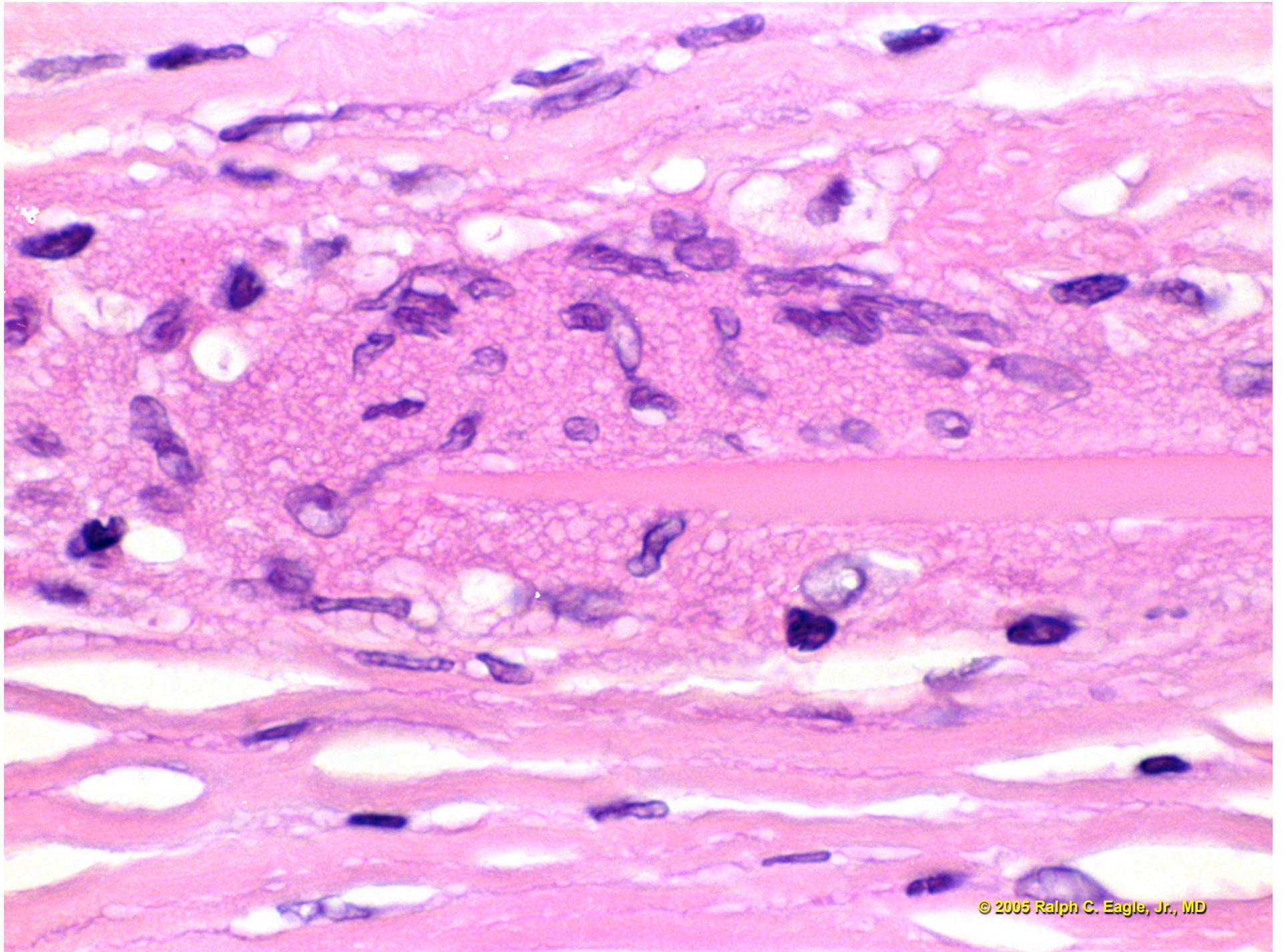
**Acanthamoeba keratitis**

**Acanthameba keratitis**

**Amoebic cyst**







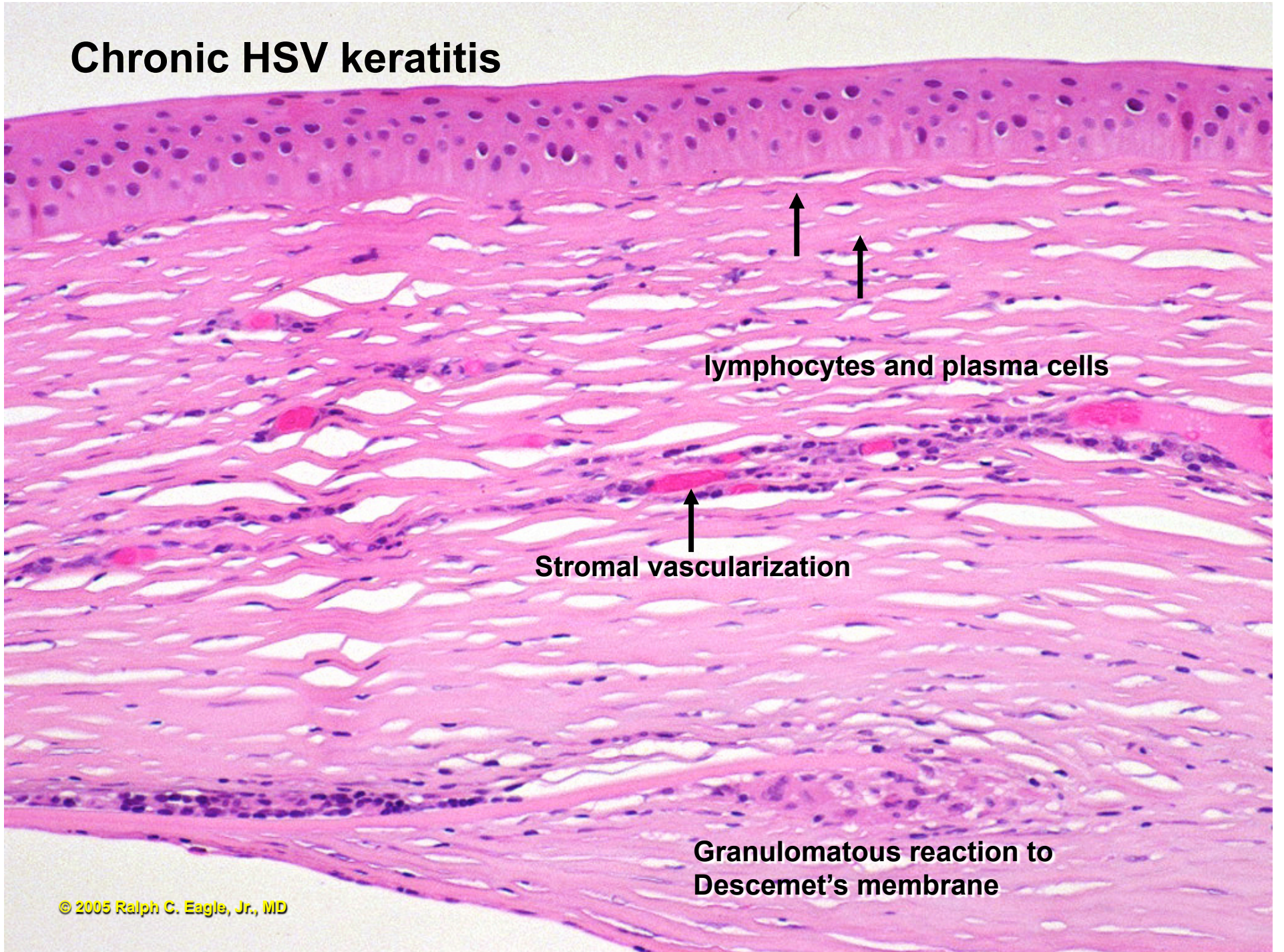
# Old HSV keratitis

Stromal thinning and loss, scarring, vascularization

Chronic inflammation (lymphocytes, plasma cells,  
epithelioid cells)

Giant cell reaction to Descemet's membrane  
(nonspecific, but typical)

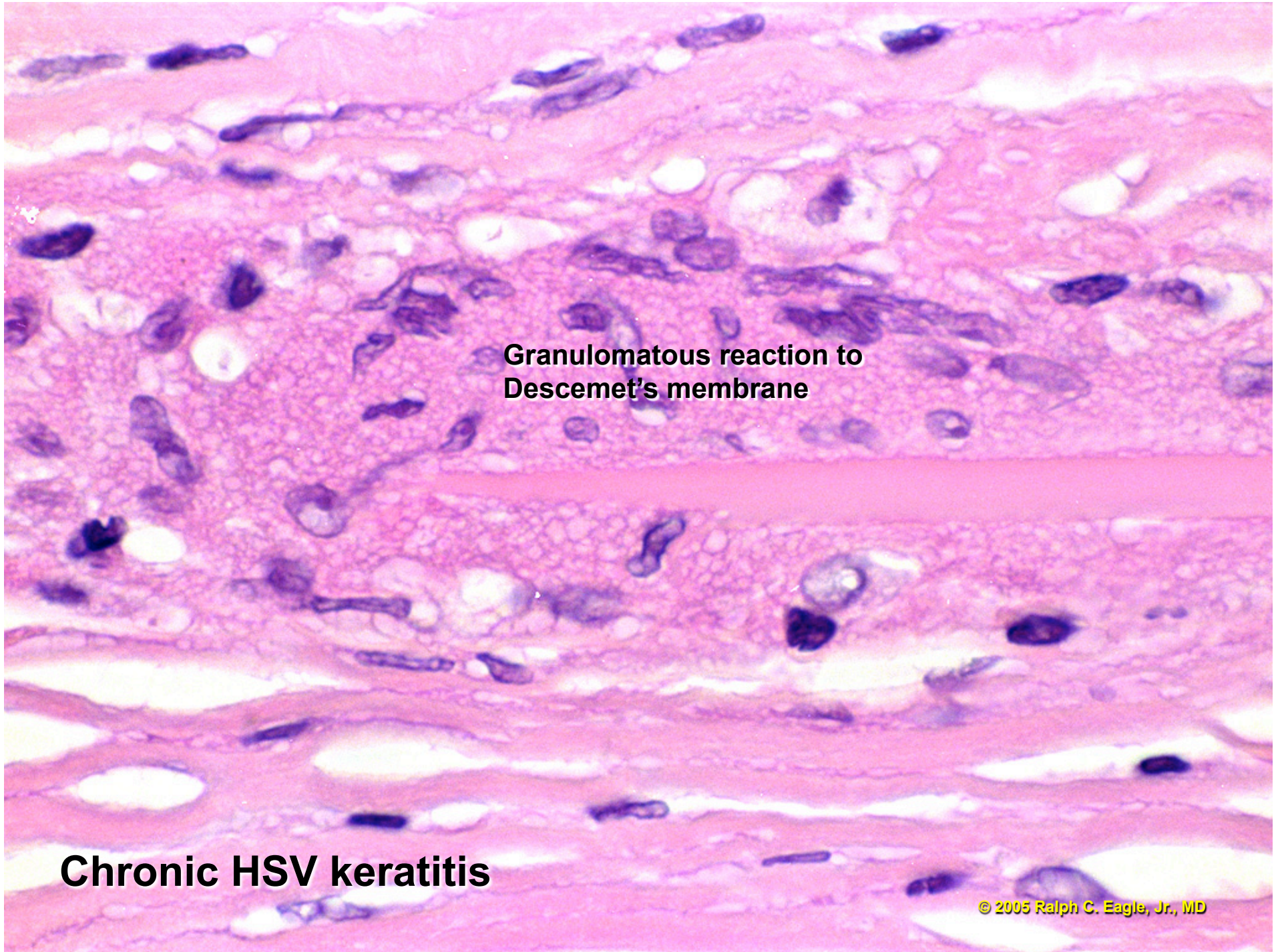
# Chronic HSV keratitis



lymphocytes and plasma cells

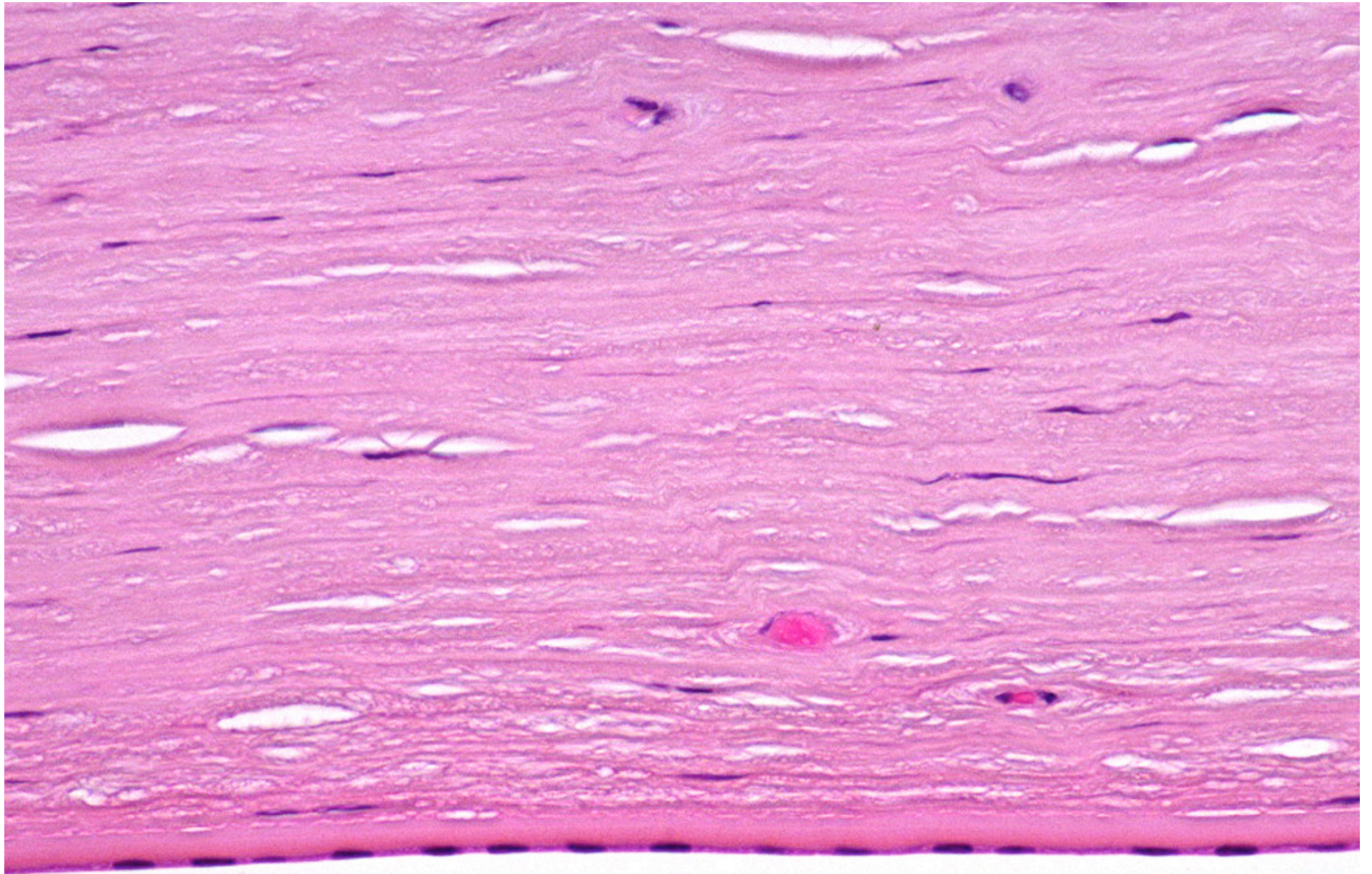
Stromal vascularization

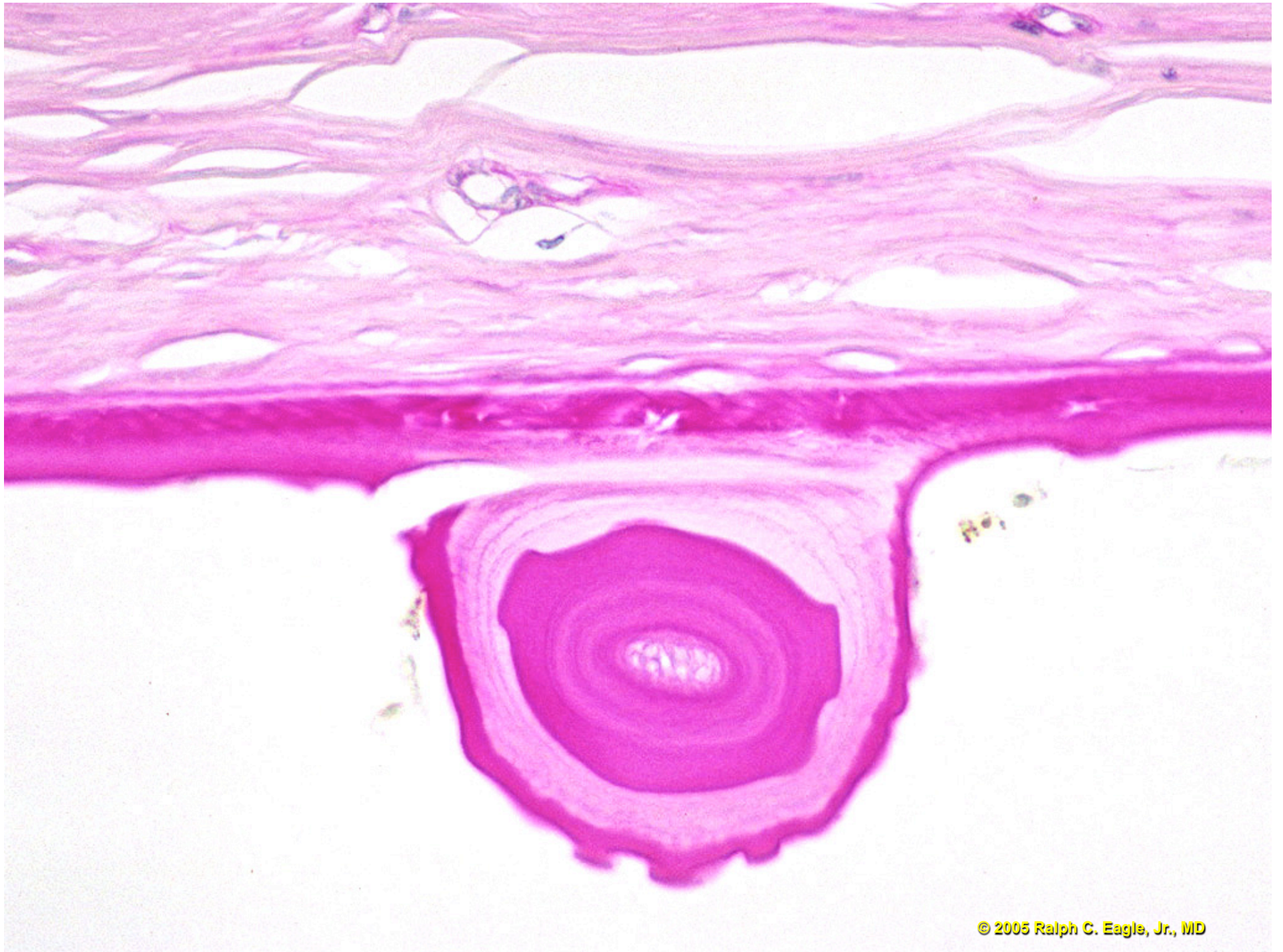
Granulomatous reaction to Descemet's membrane



**Granulomatous reaction to  
Descemet's membrane**

**Chronic HSV keratitis**





## **Chronic Luetic Interstitial Keratitis**

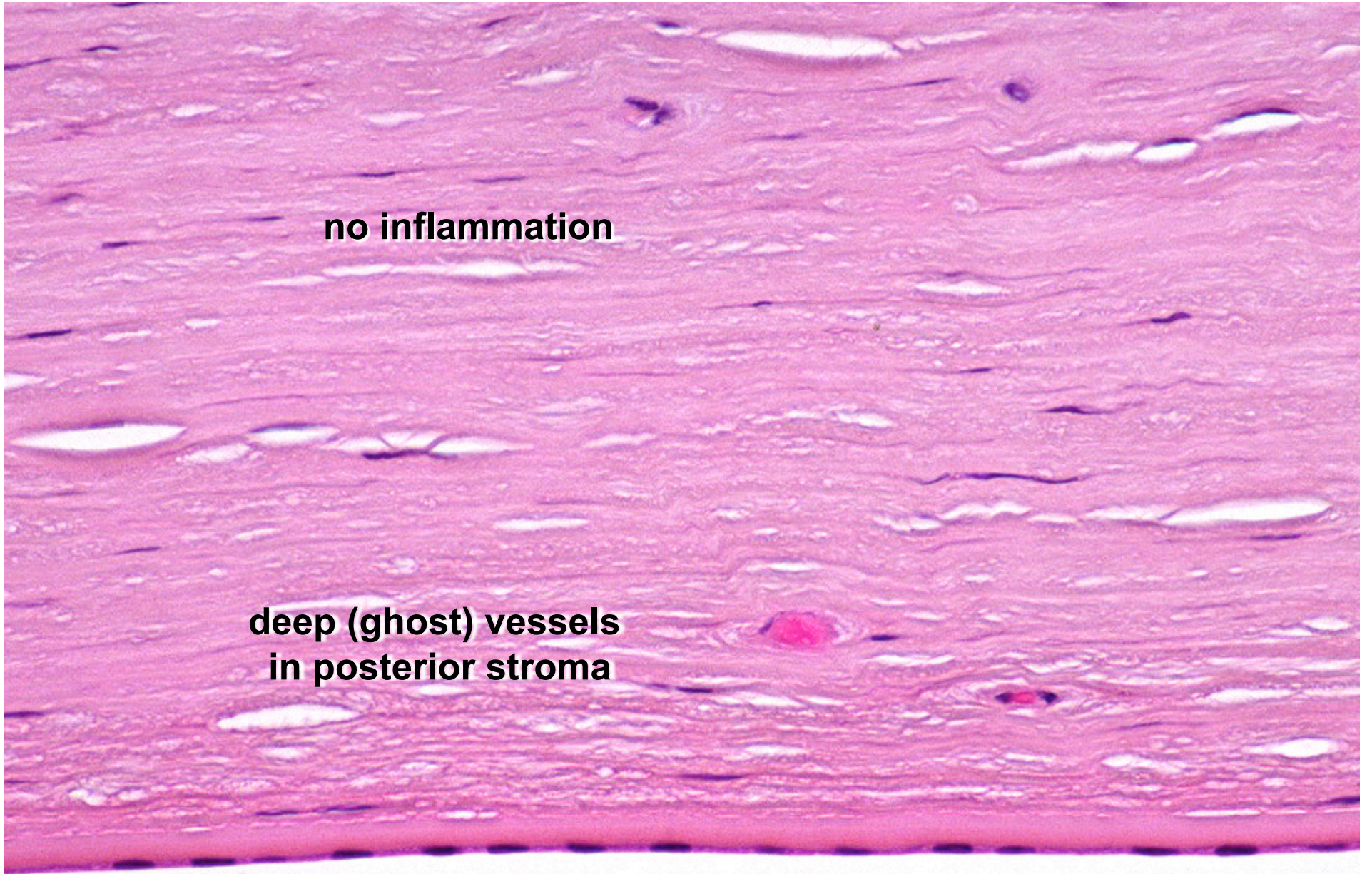
No inflammation

Deep vessels in posterior stroma

Descemet's membrane may show irregular  
guttae and thickening

Anterior scarring and stromal loss in some

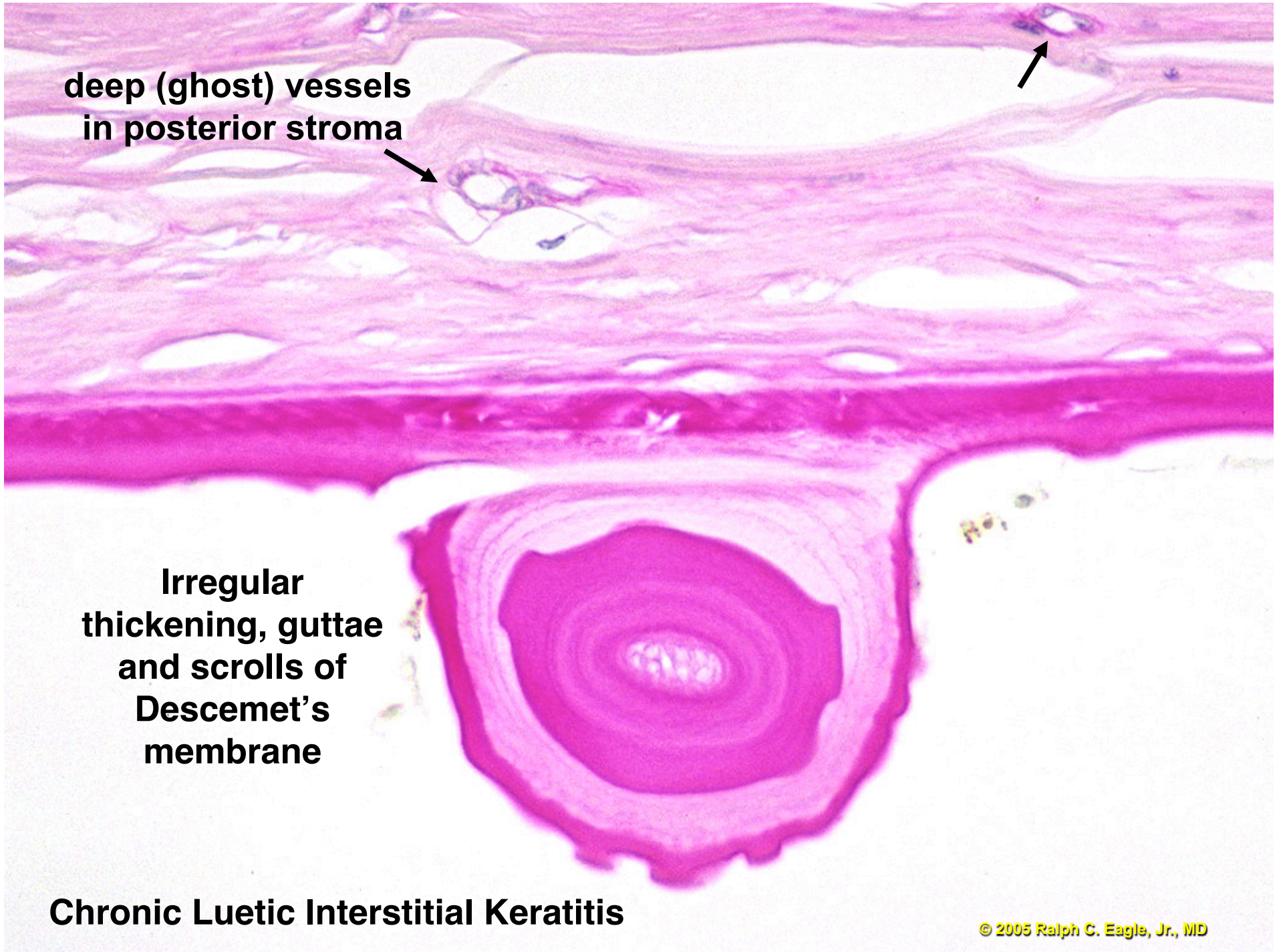
Moth-eaten, finely vacuolated stroma



**no inflammation**

**deep (ghost) vessels  
in posterior stroma**

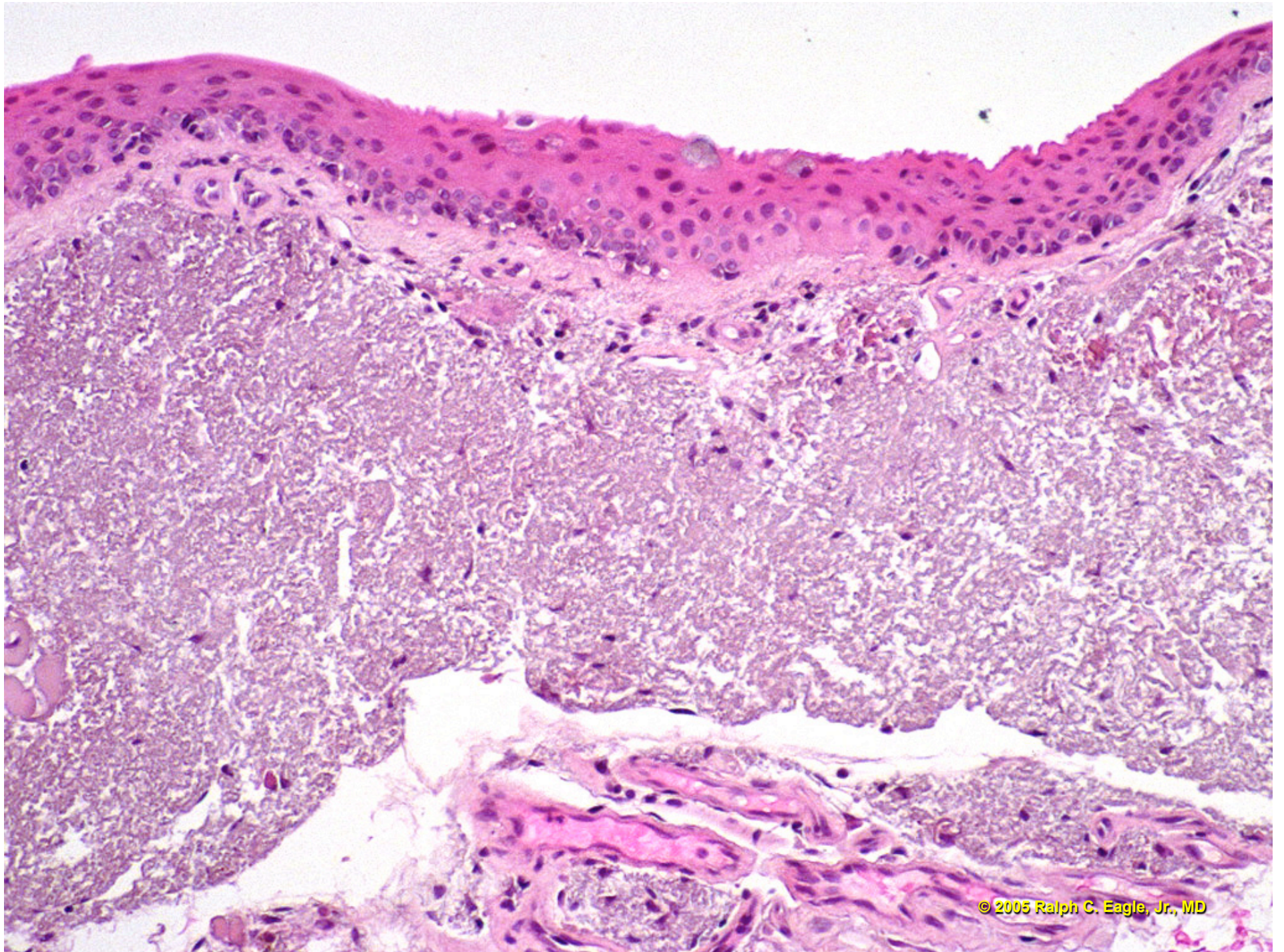
## **Chronic Luetic Interstitial Keratitis**

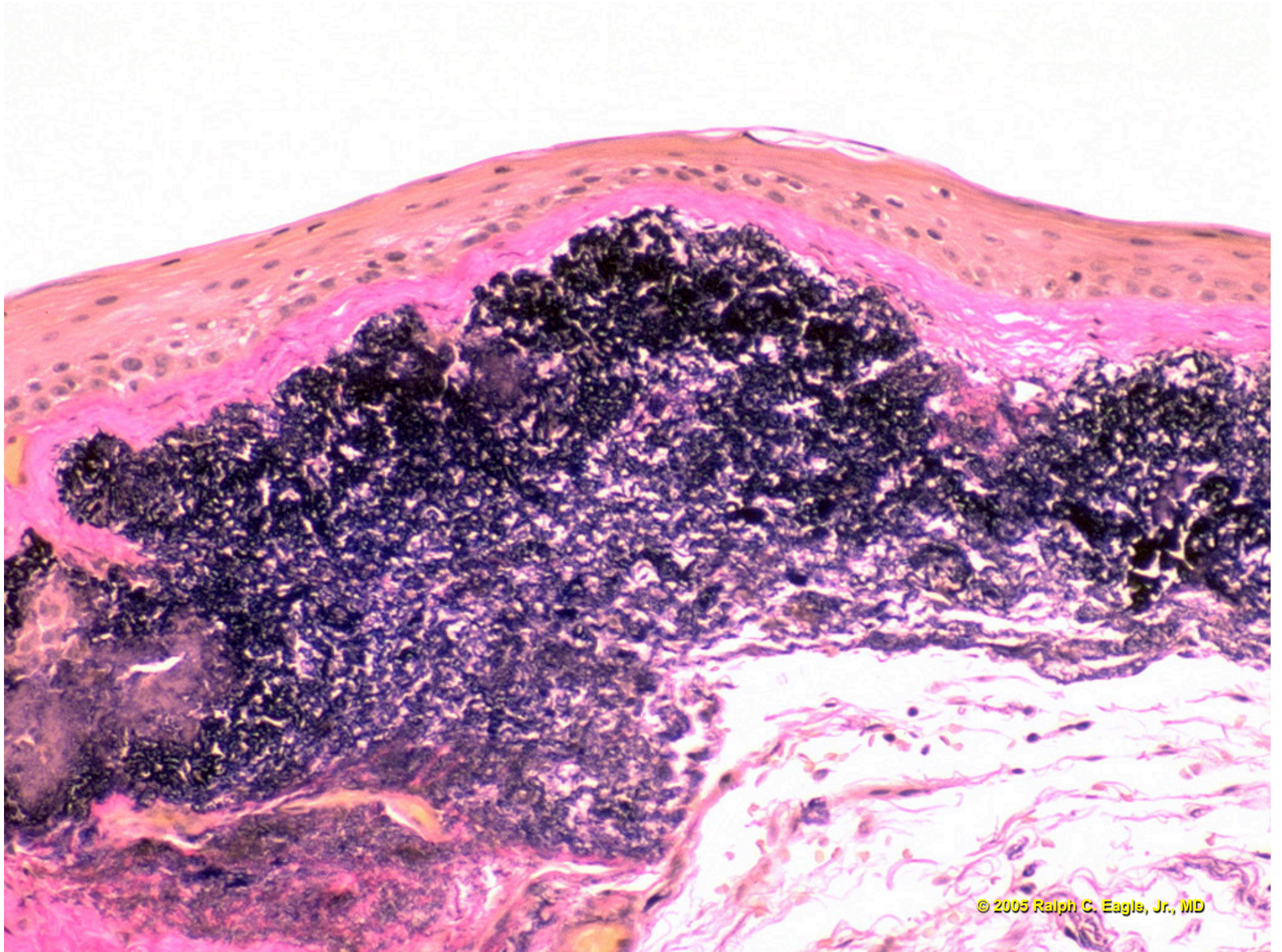


**deep (ghost) vessels  
in posterior stroma**

**Irregular  
thickening, guttae  
and scrolls of  
Descemet's  
membrane**

**Chronic Luetic Interstitial Keratitis**



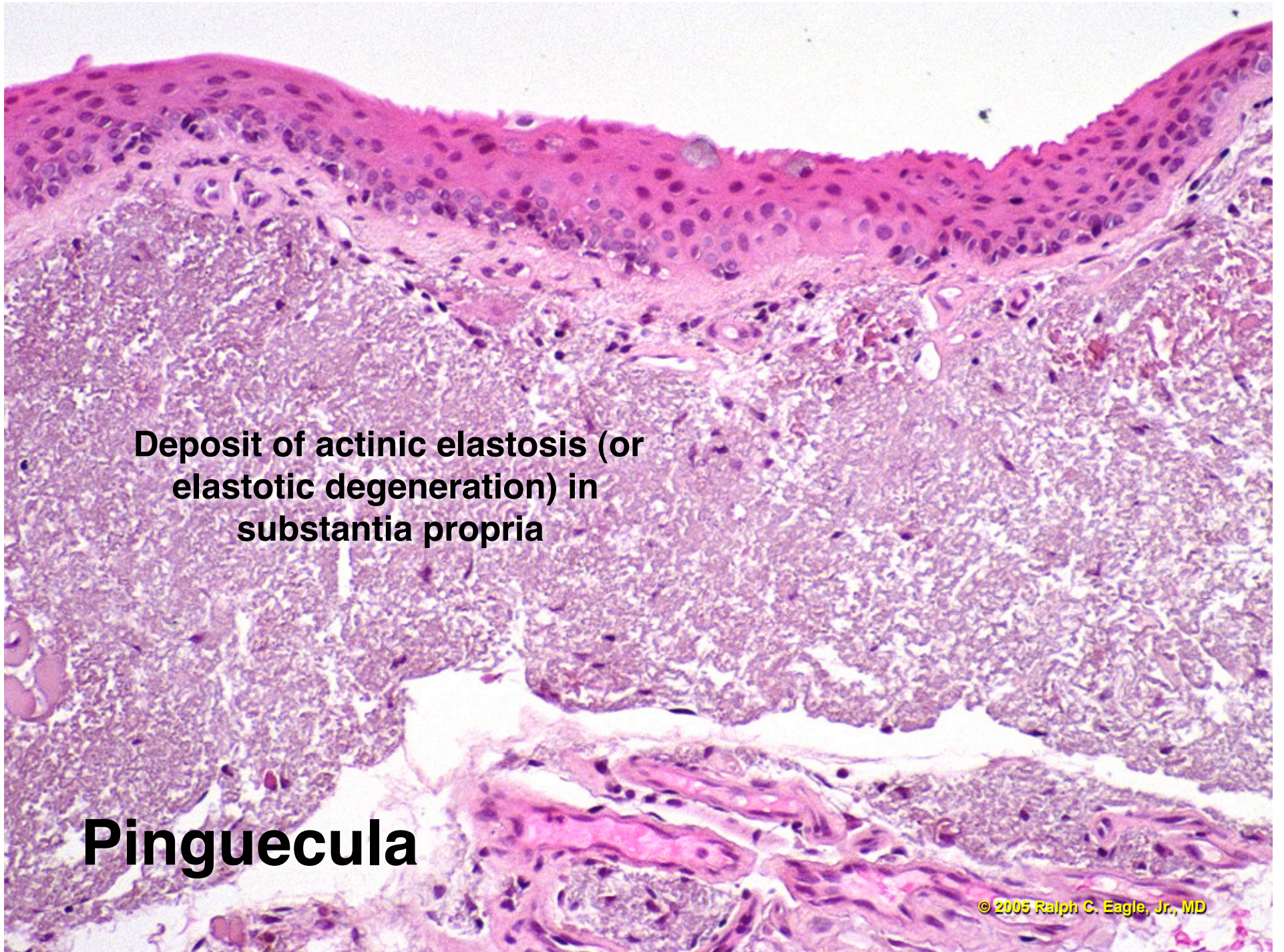


# Pinguecula

Acellular avascular mass of grayish material  
(actinic elastosis) in substantia propria

May be granular or hyalinized

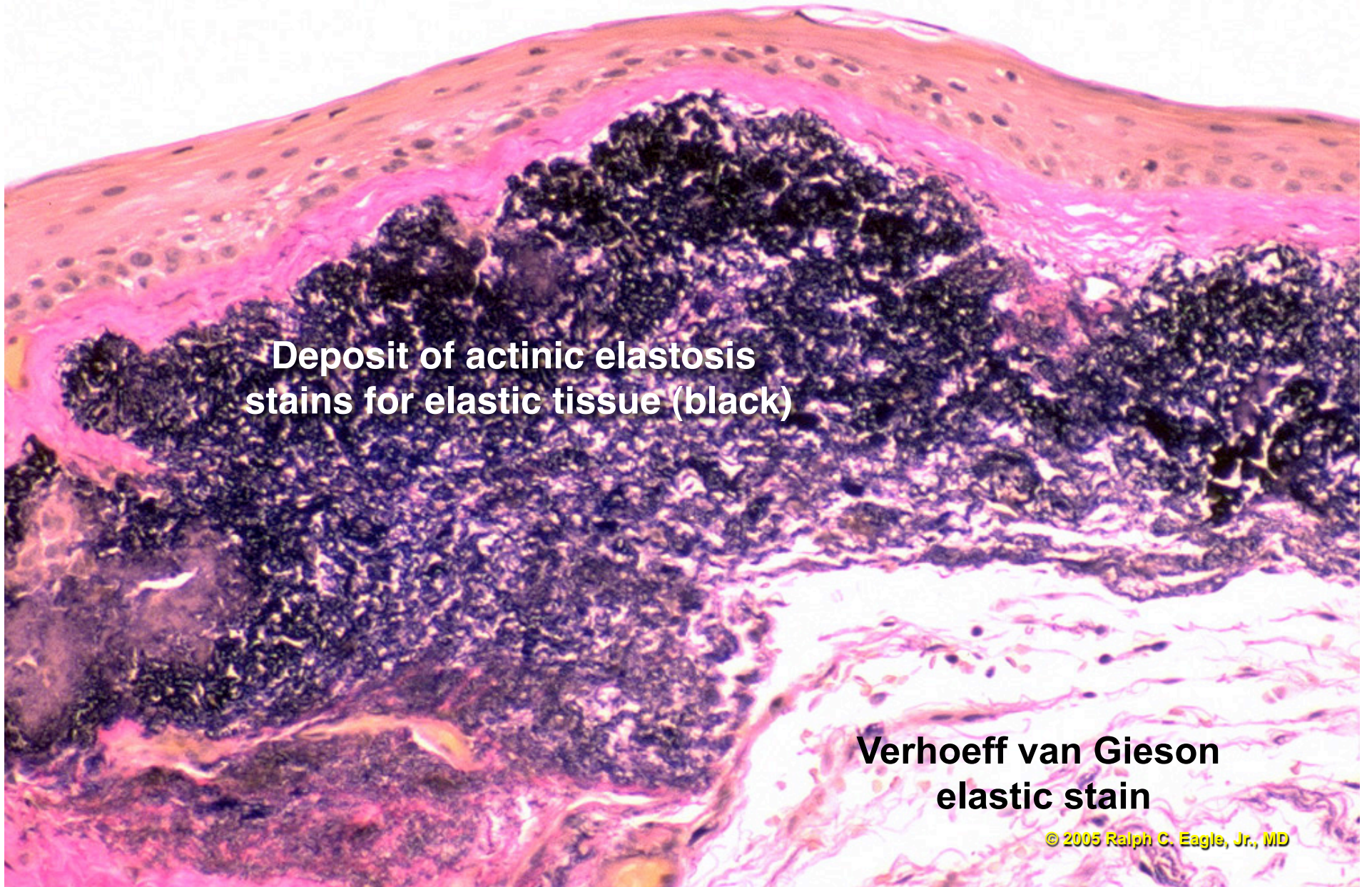
Thickened worm-like collagen fibers (vermiform  
degeneration)



**Deposit of actinic elastosis (or  
elastotic degeneration) in  
substantia propria**

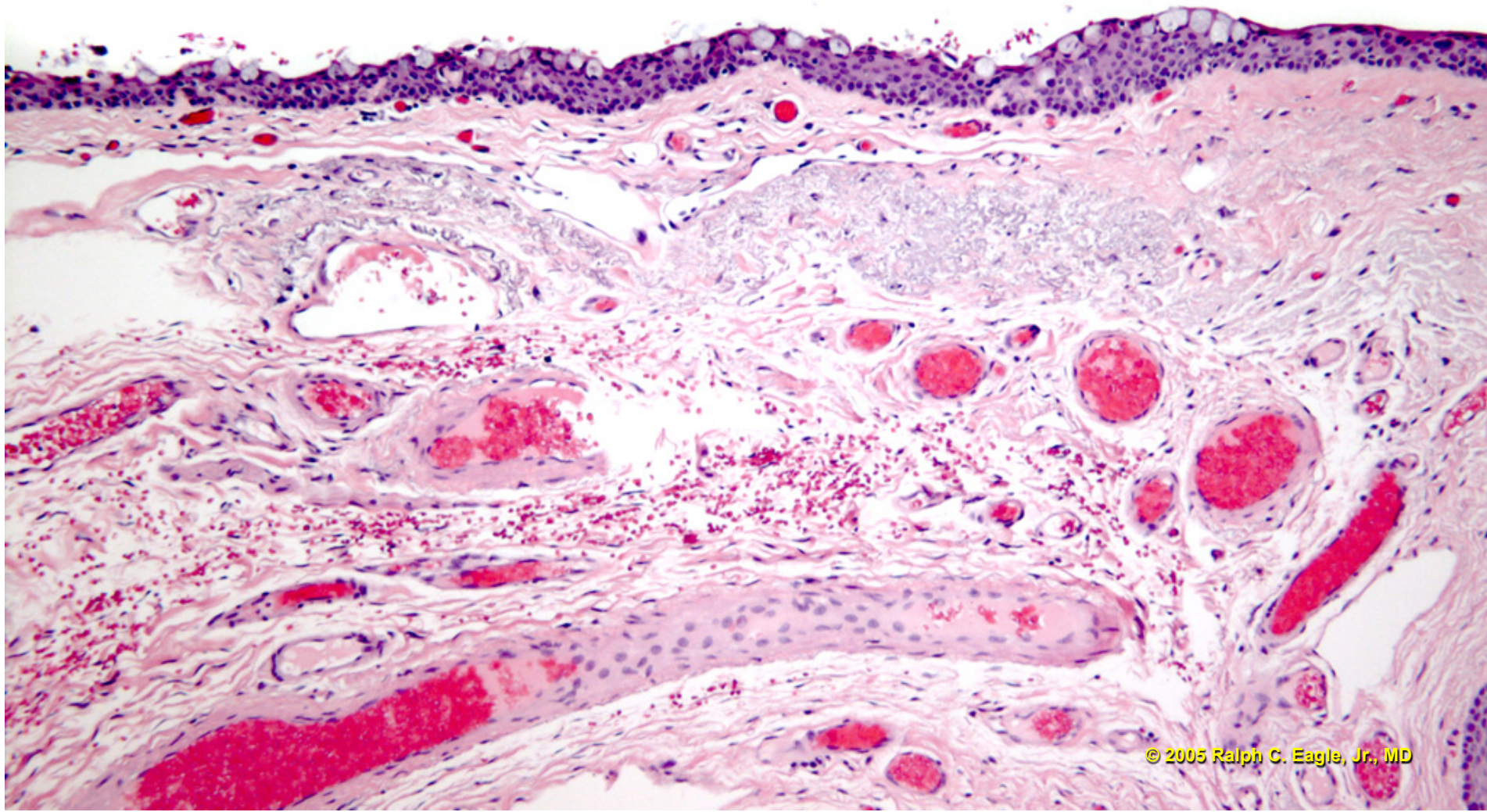
**Pinguecula**

# Pinguecula



**Deposit of actinic elastosis  
stains for elastic tissue (black)**

**Verhoeff van Gieson  
elastic stain**



# Pterygium

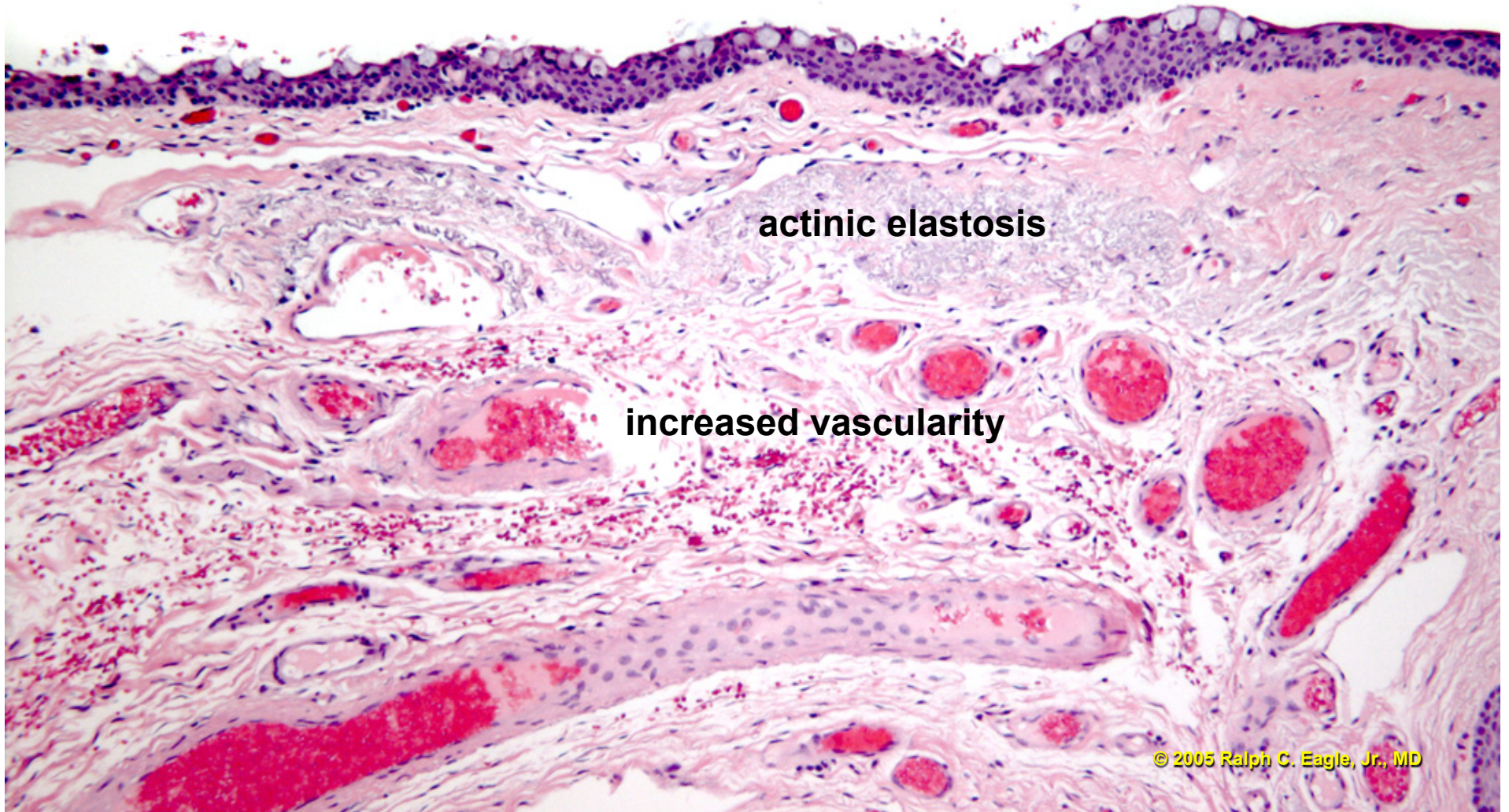
Substantial propria often contains foci of actinic elastosis (like pinguecula)  
Increased vascularization  
Epithelium may be thickened

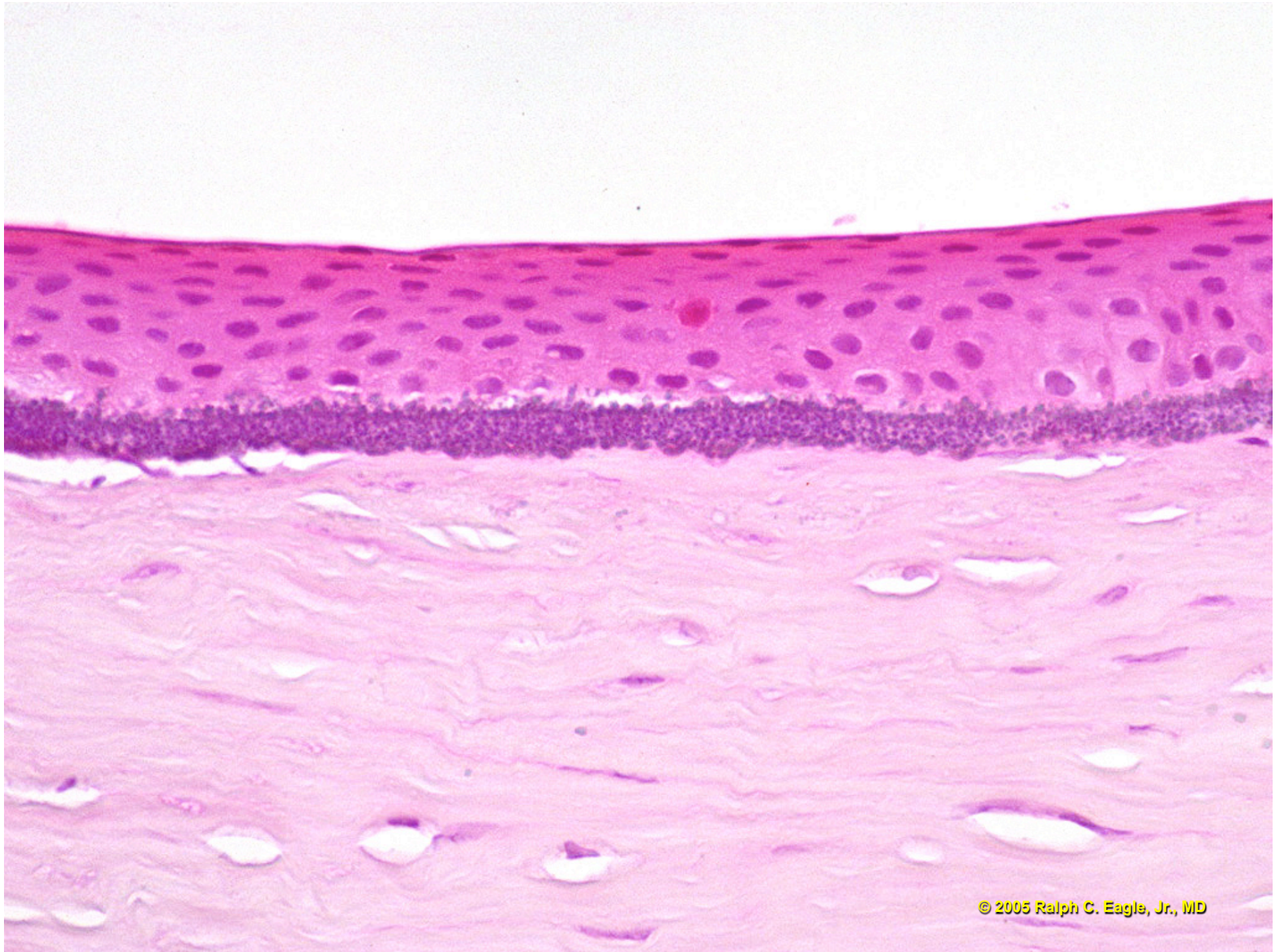# Pterygium

normal conjunctival or limbal epithelium

actinic elastosis

increased vascularity



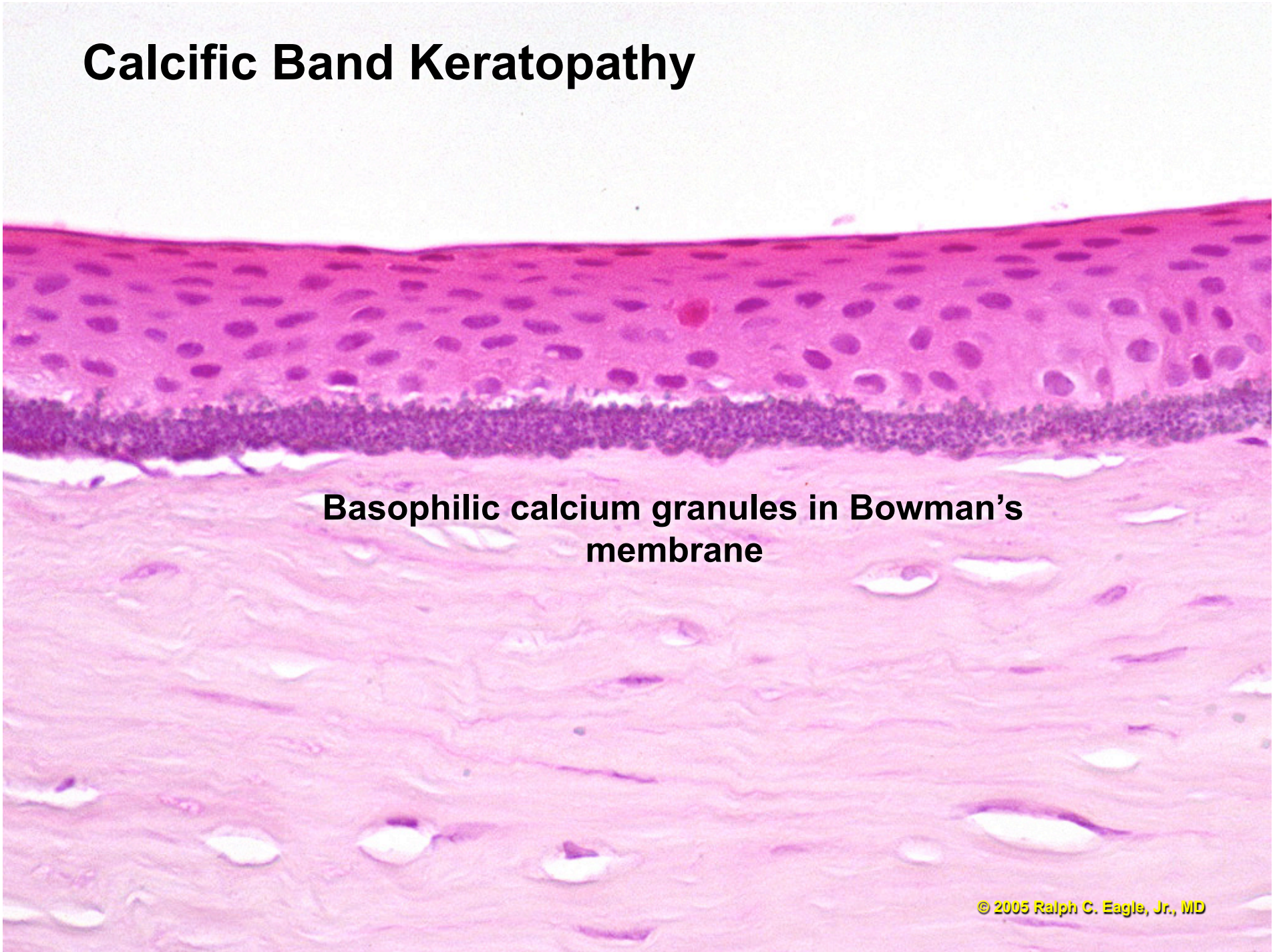


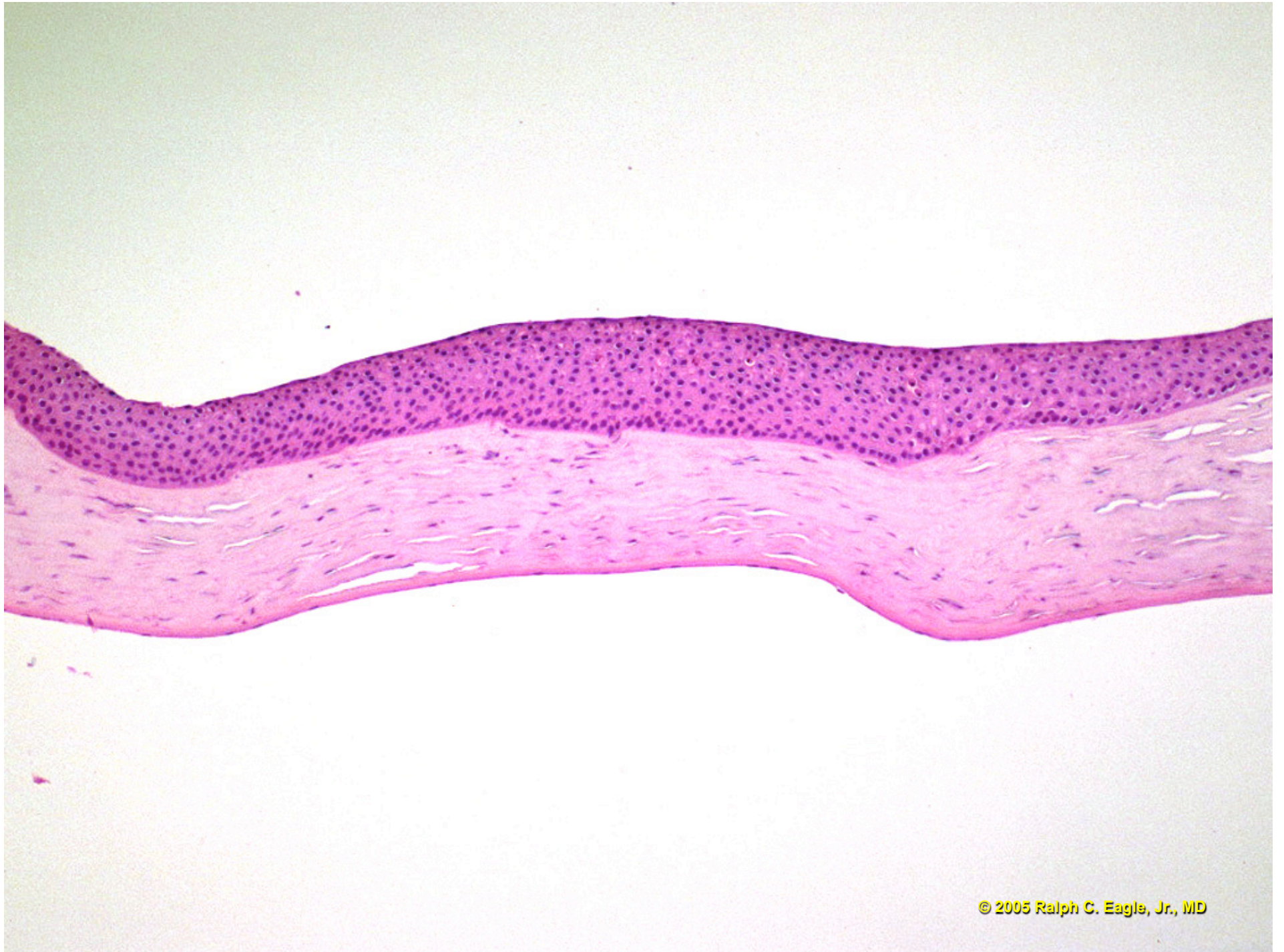# **Calcific Band Keratopathy**

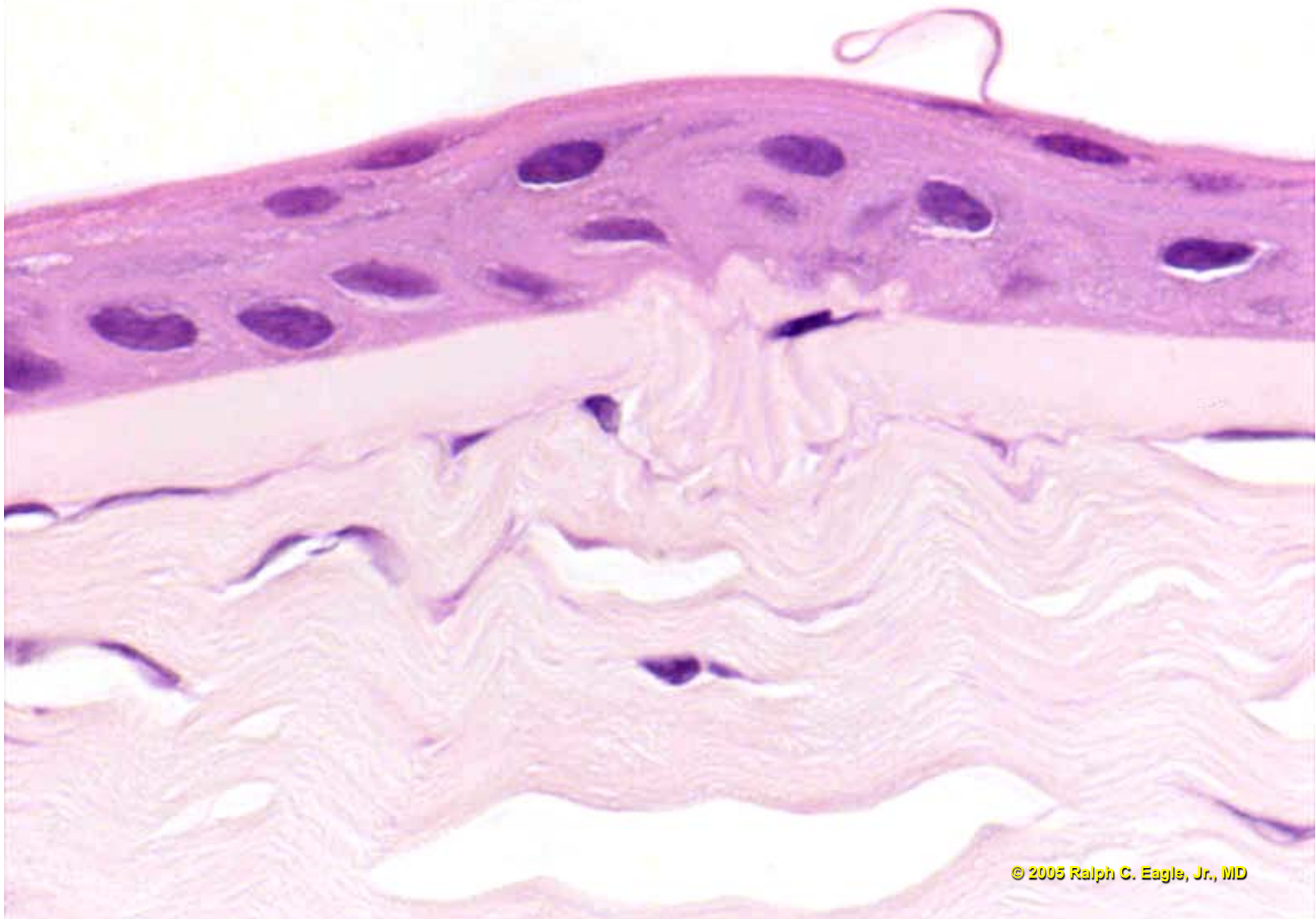Basophilic granules (basophilic stippling) of calcium in Bowman's layer, anterior stroma

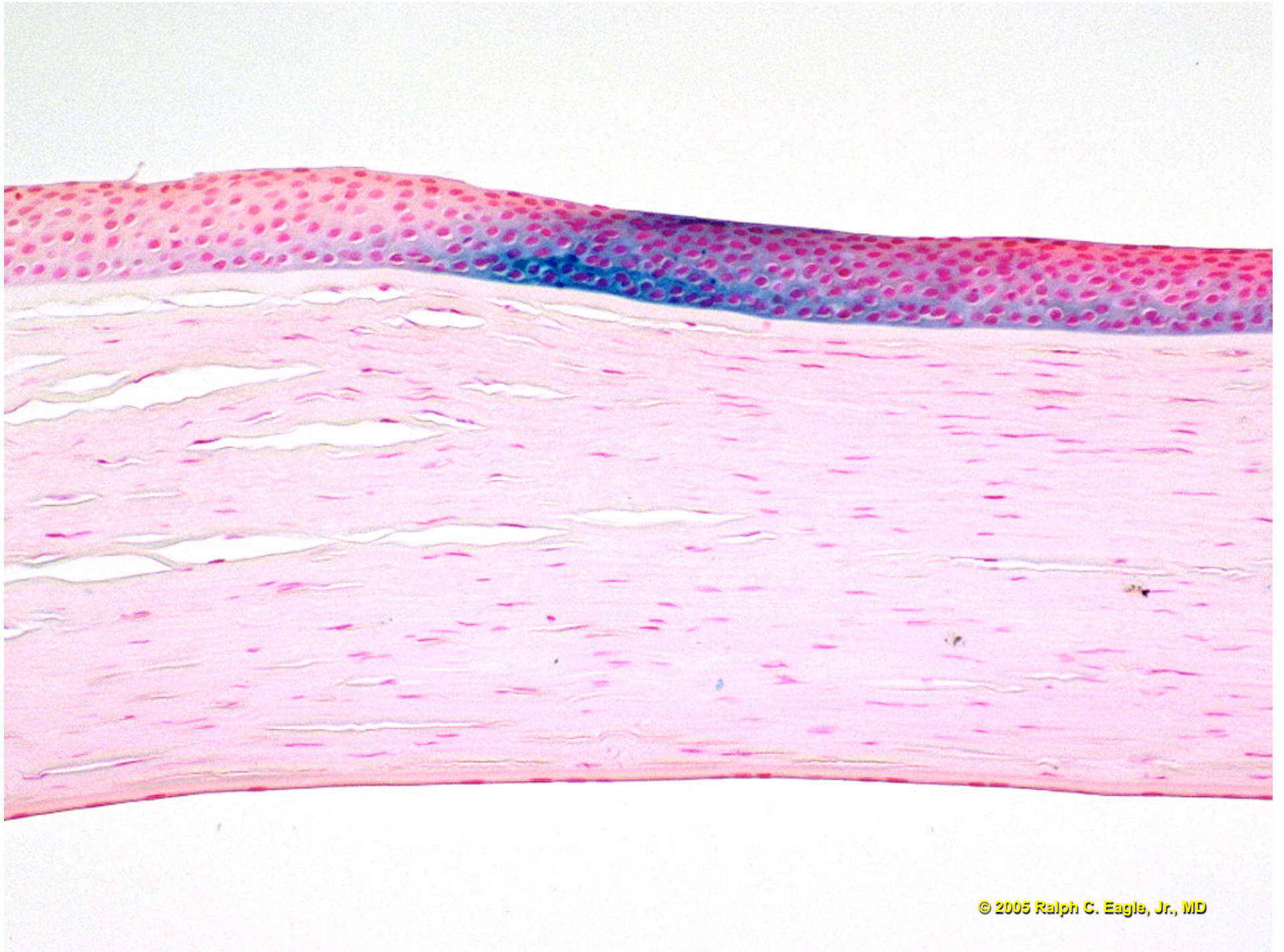
# Calcific Band Keratopathy

**Basophilic calcium granules in Bowman's membrane**









# Keratoconus

Corneal stroma thinned centrally, often scarred

Small wavy dehiscences in Bowman's layer

Epithelium irregular, with thinning and compensatory hyperplasia

Descemet's membrane thin, endothelium healthy

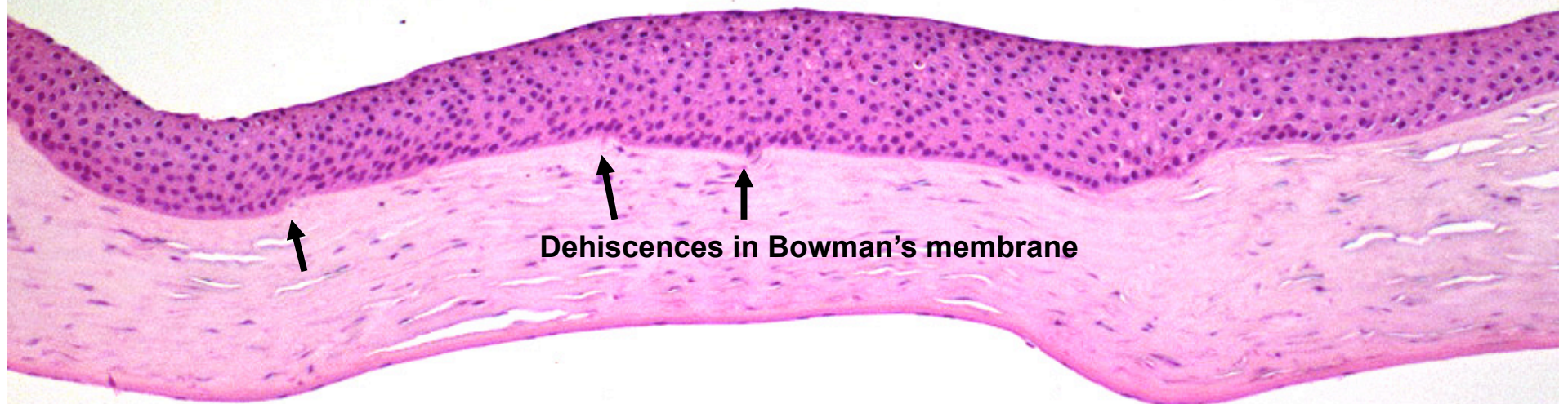Look for healed Descemet's breaks (after acute hydrops)

Cornea often looks wavy at low magnifications

Iron in epithelium around cone (Fleischer ring )

# Keratoconus

Irregular epithelium, compensatory epithelial hyperplasia

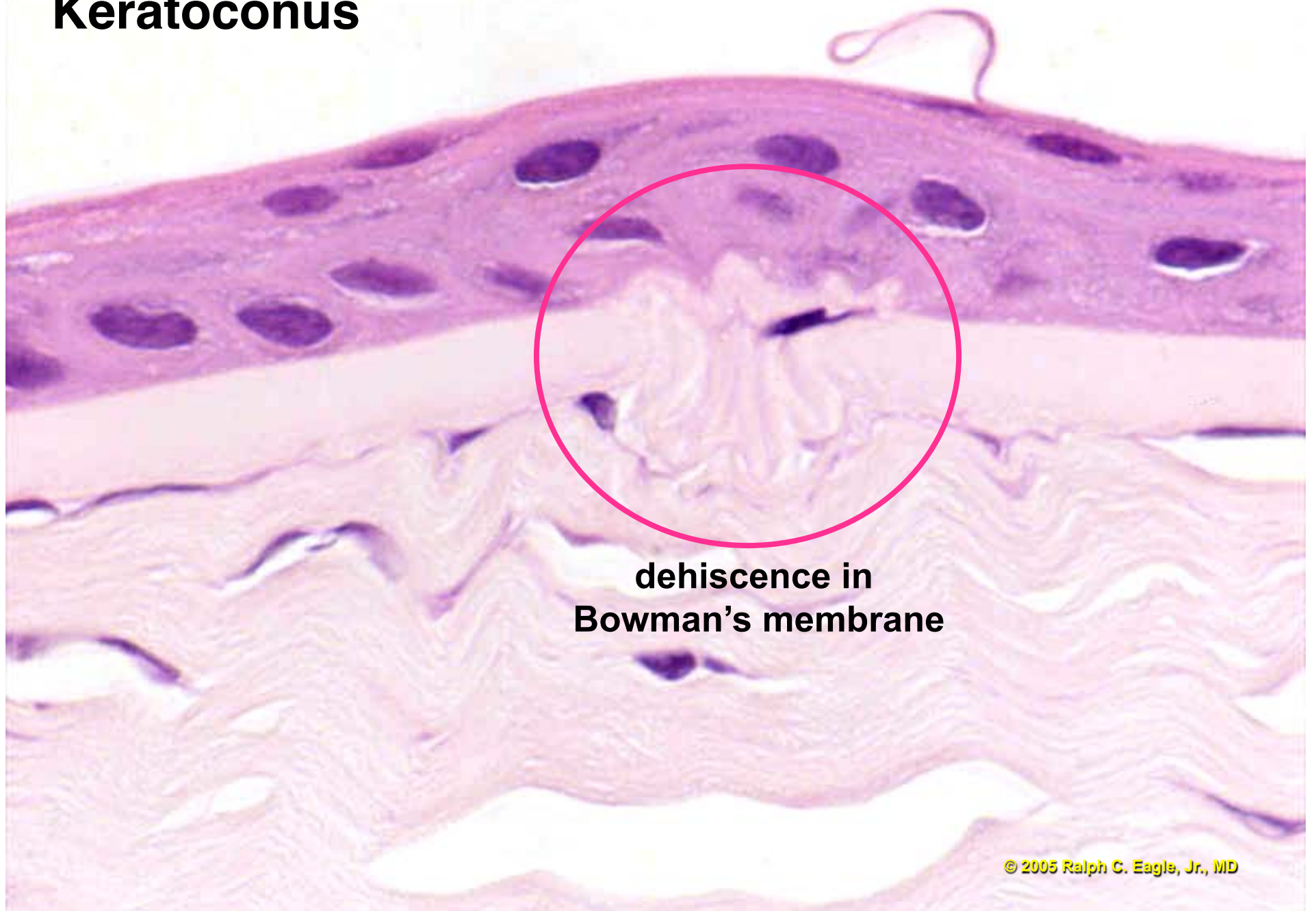


Dehiscences in Bowman's membrane

ectasia of central cornea

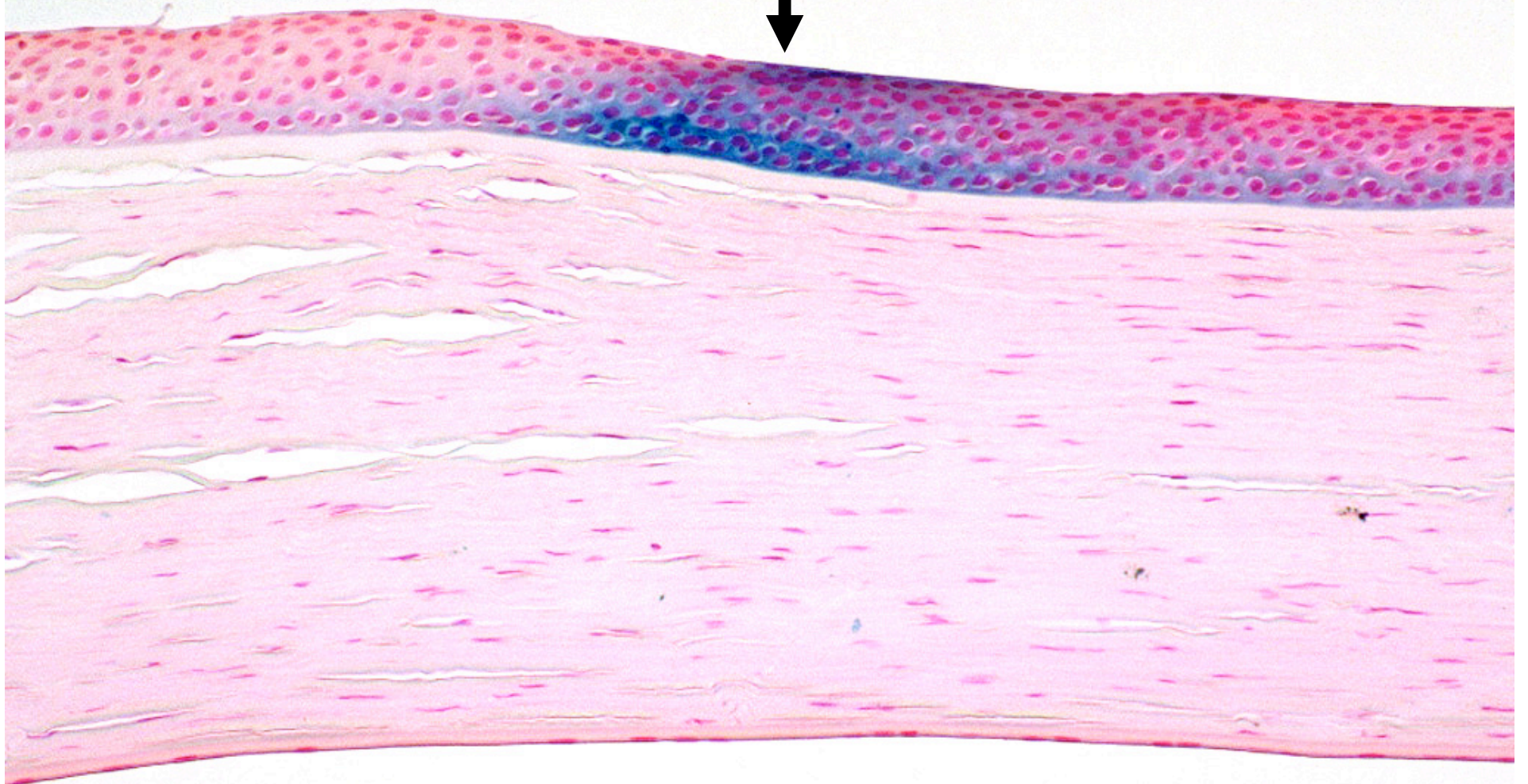
cornea has abnormal wavy conformation

# Keratoconus



**dehiscence in  
Bowman's membrane**

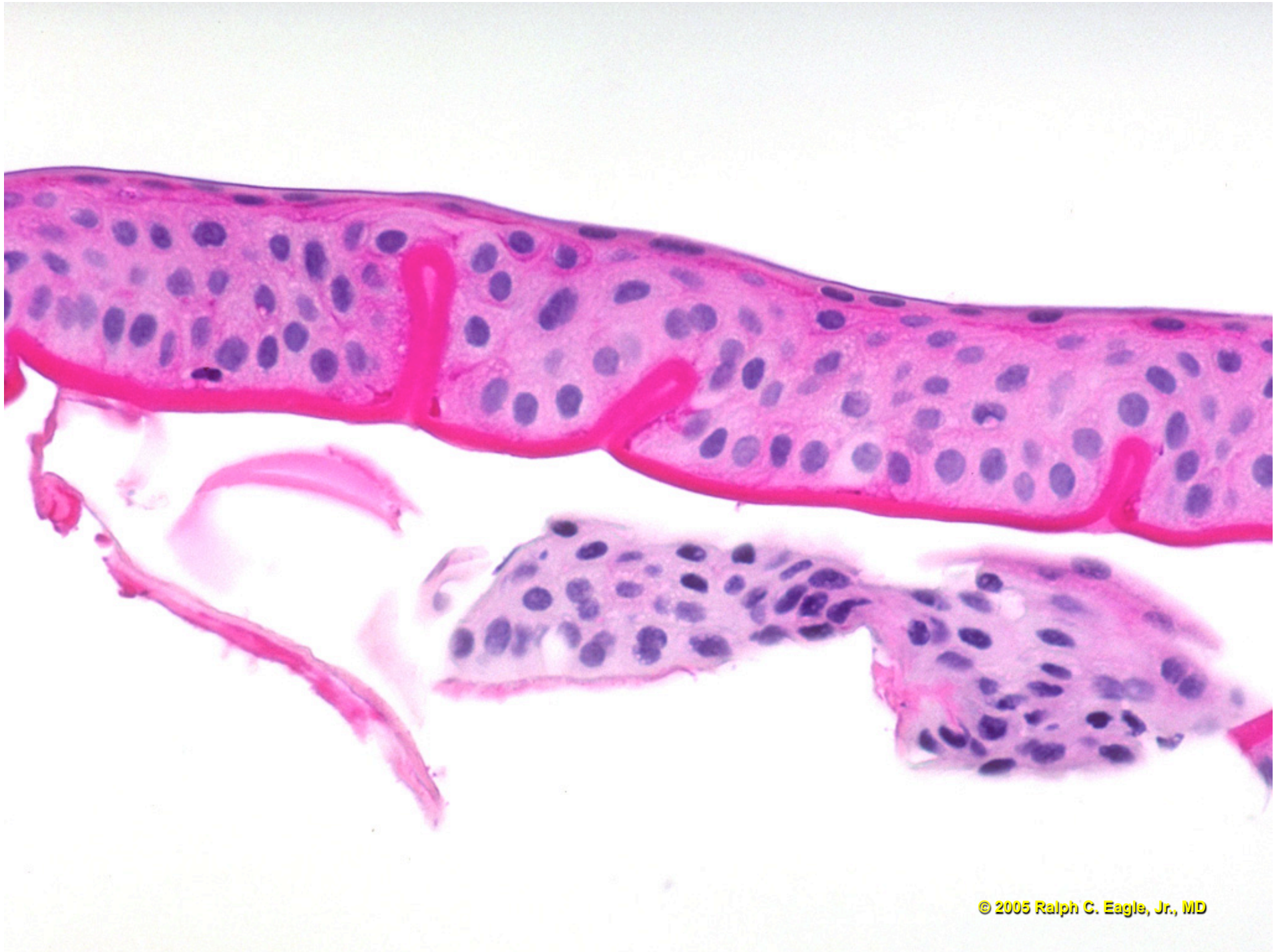**focal deposit of iron in  
corneal epithelium**

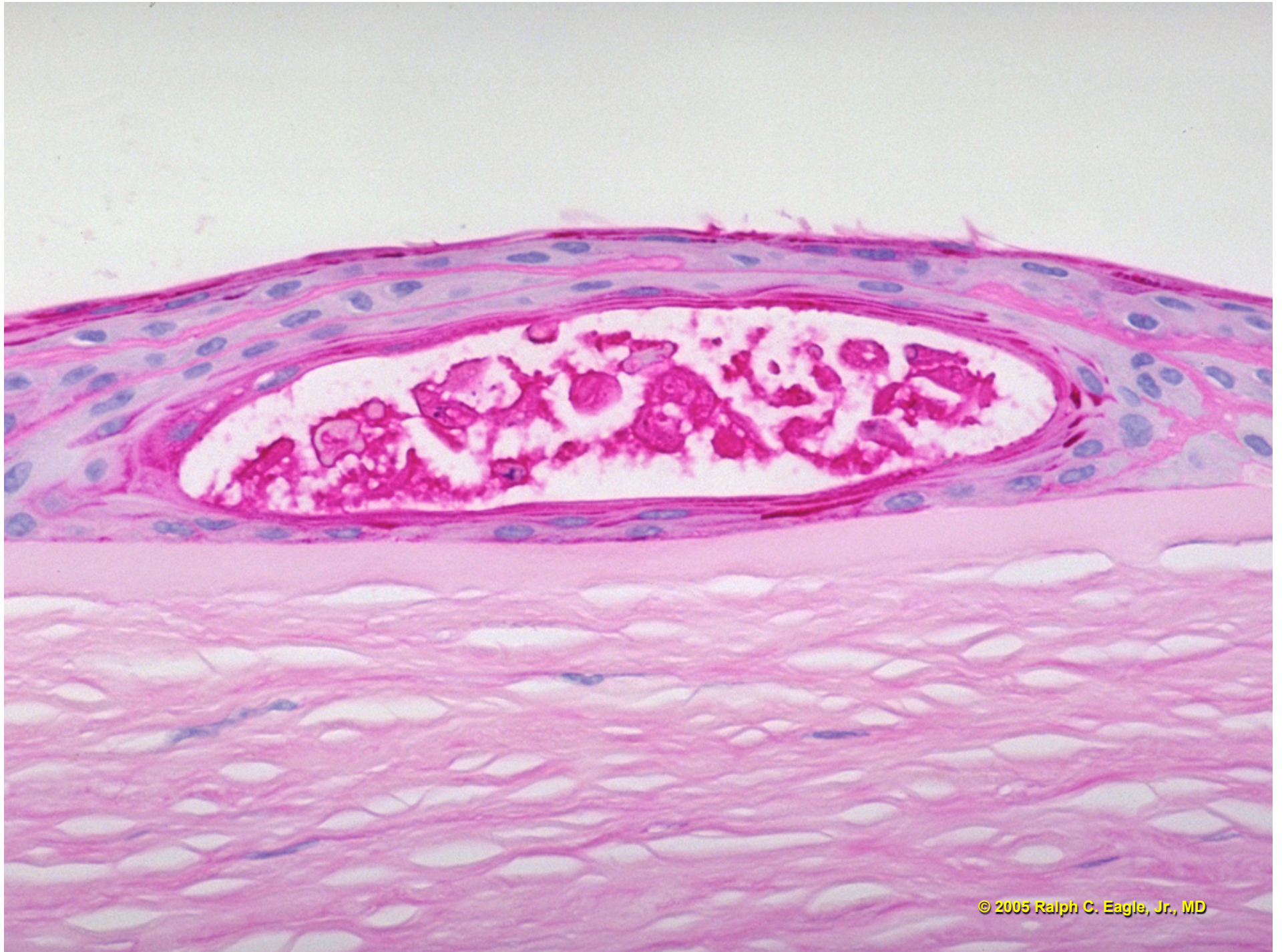

**Keratoconus - Fleischer ring**

**Iron stain**

© 2005 Ralph C. Eagle, Jr., MD





# **Anterior Basement Membrane Dystrophy (“Map, Dot, Fingerprint”)**

Reduplication of corneal epithelium

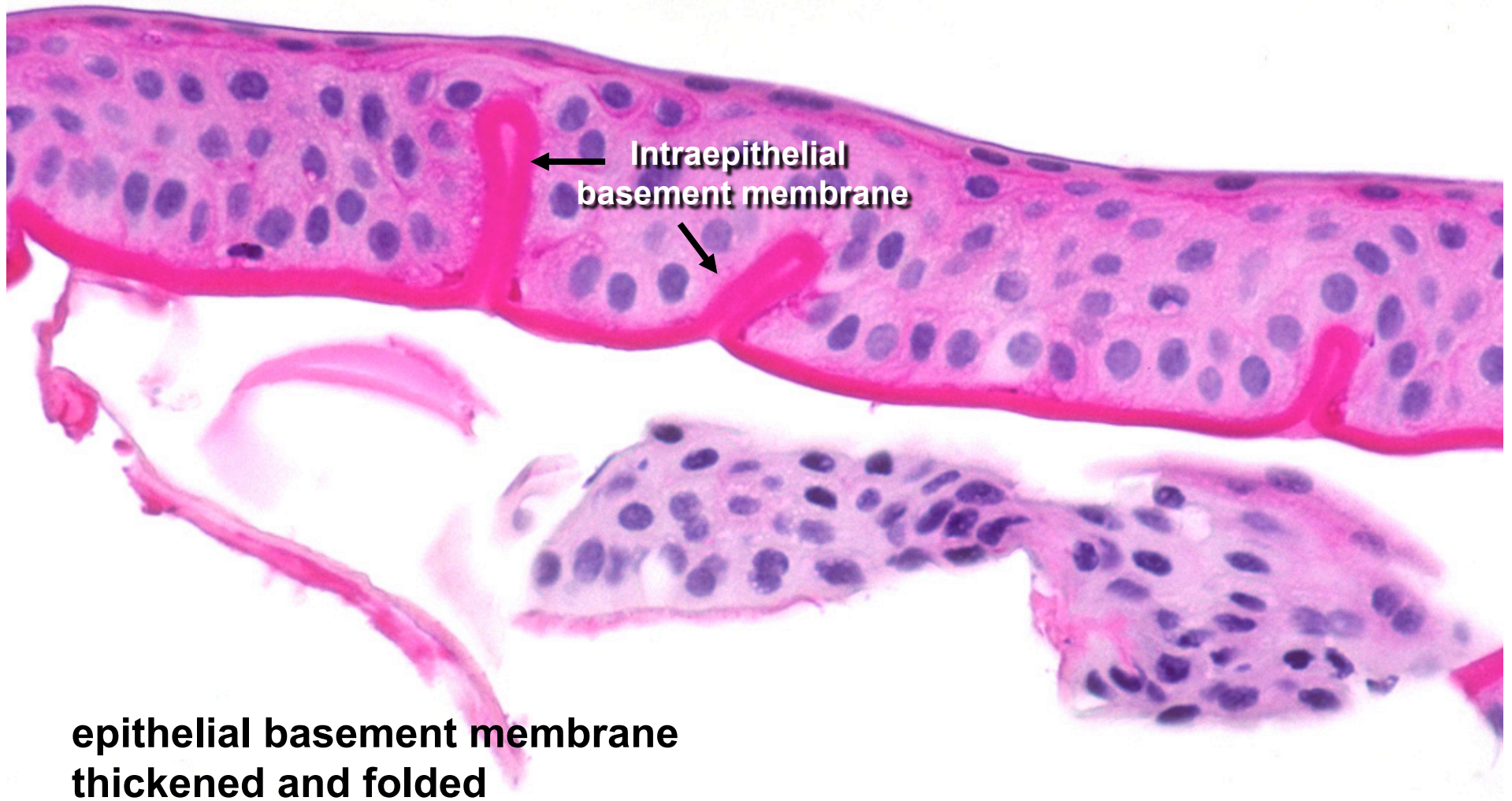
Bands of intraepithelial basement membrane

Cystoid spaces filled with necrotic epithelial cells  
trapped within epithelium

Epithelial basement membrane thickened, buckled

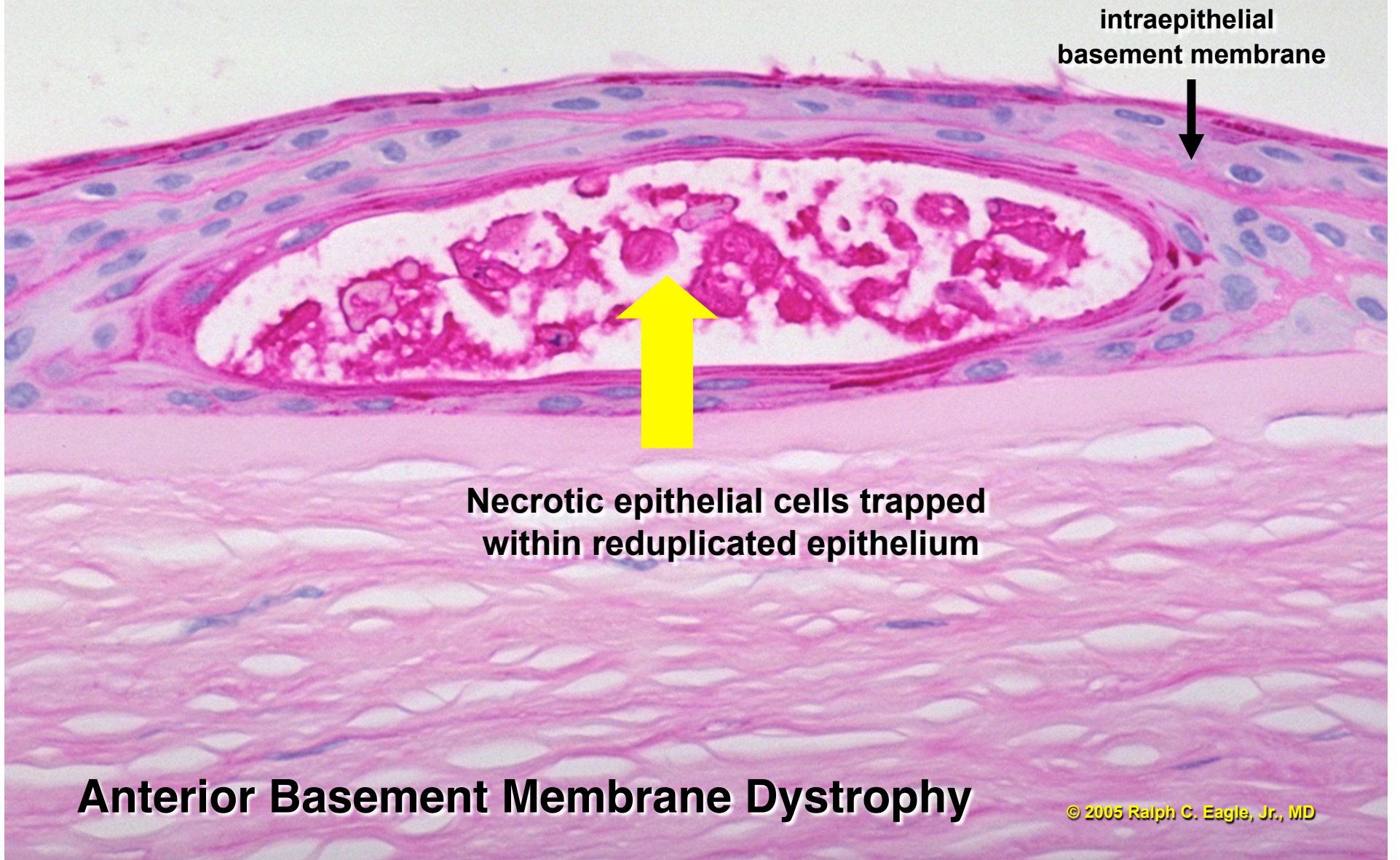
Focal pannus formation

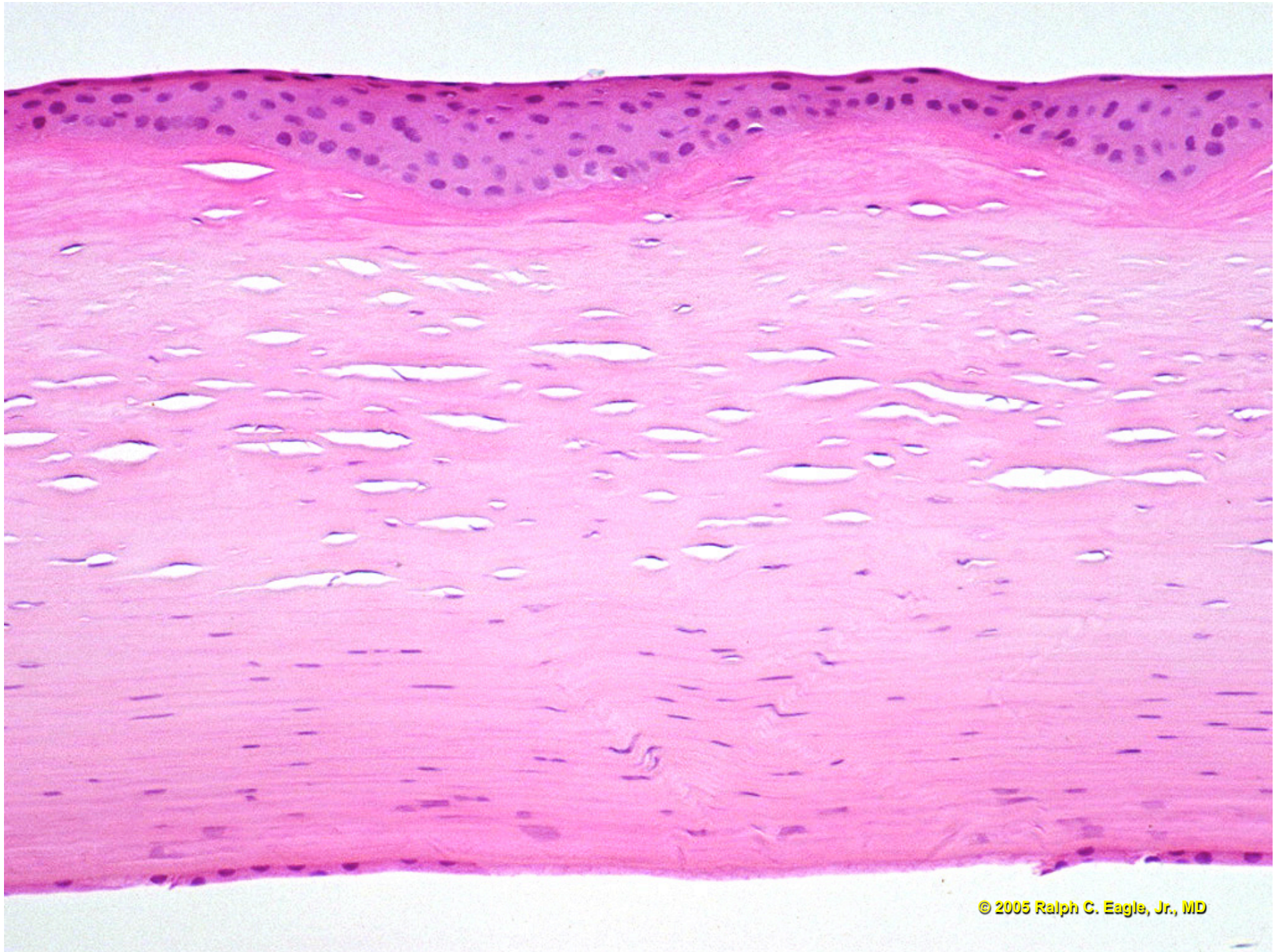# Anterior Basement Membrane Dystrophy



**PAS**

# Cogan's Microcyst - "Dot"





# Reis-Bücklers Dystrophy

Sawtoothing of corneal epithelium

Lamellated subepithelial pannus located  
anterior to stroma

Bowman's layer destroyed

Superficial variant of granular dystrophy

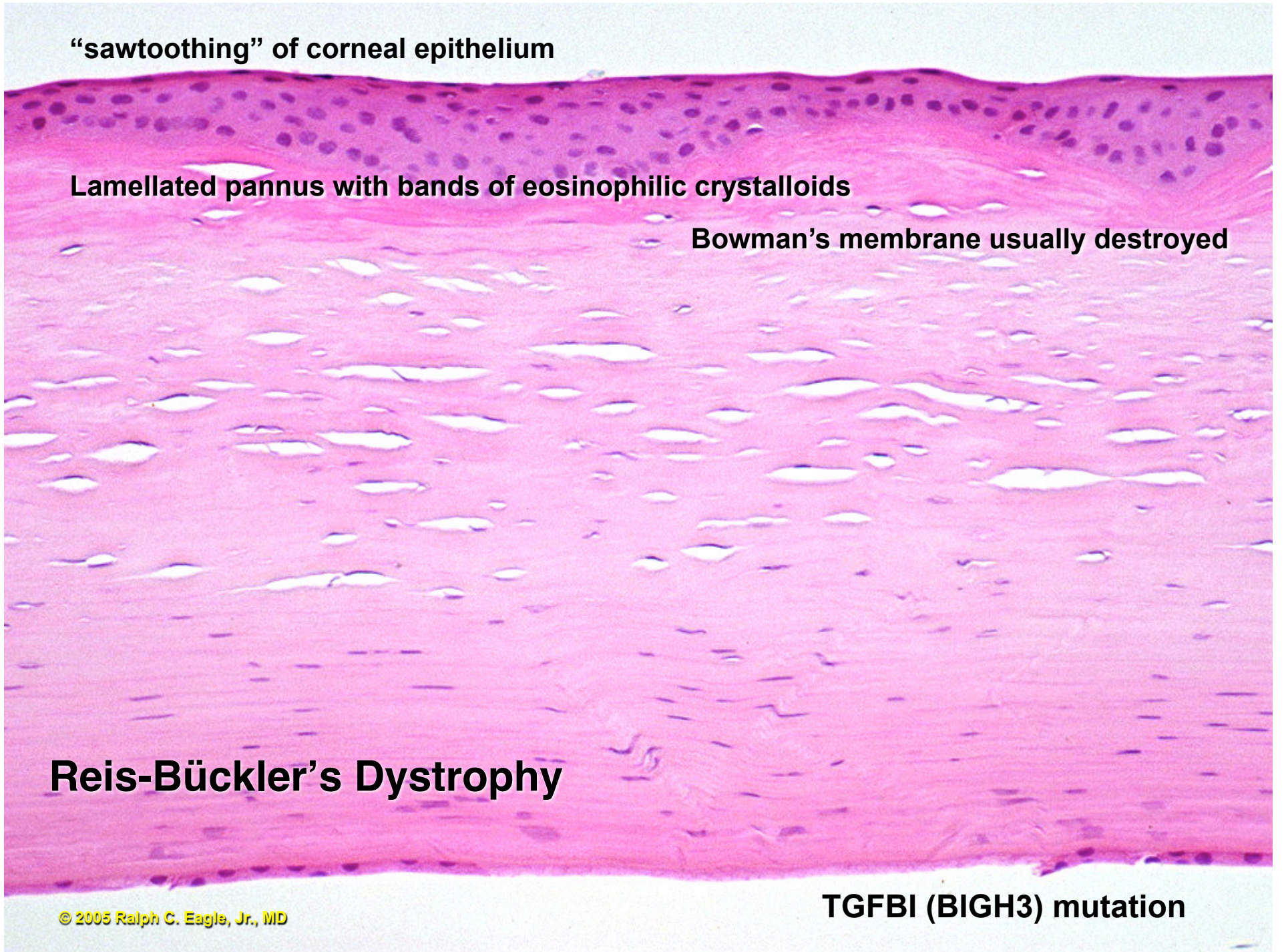
TGFBI (BIGH3) mutation

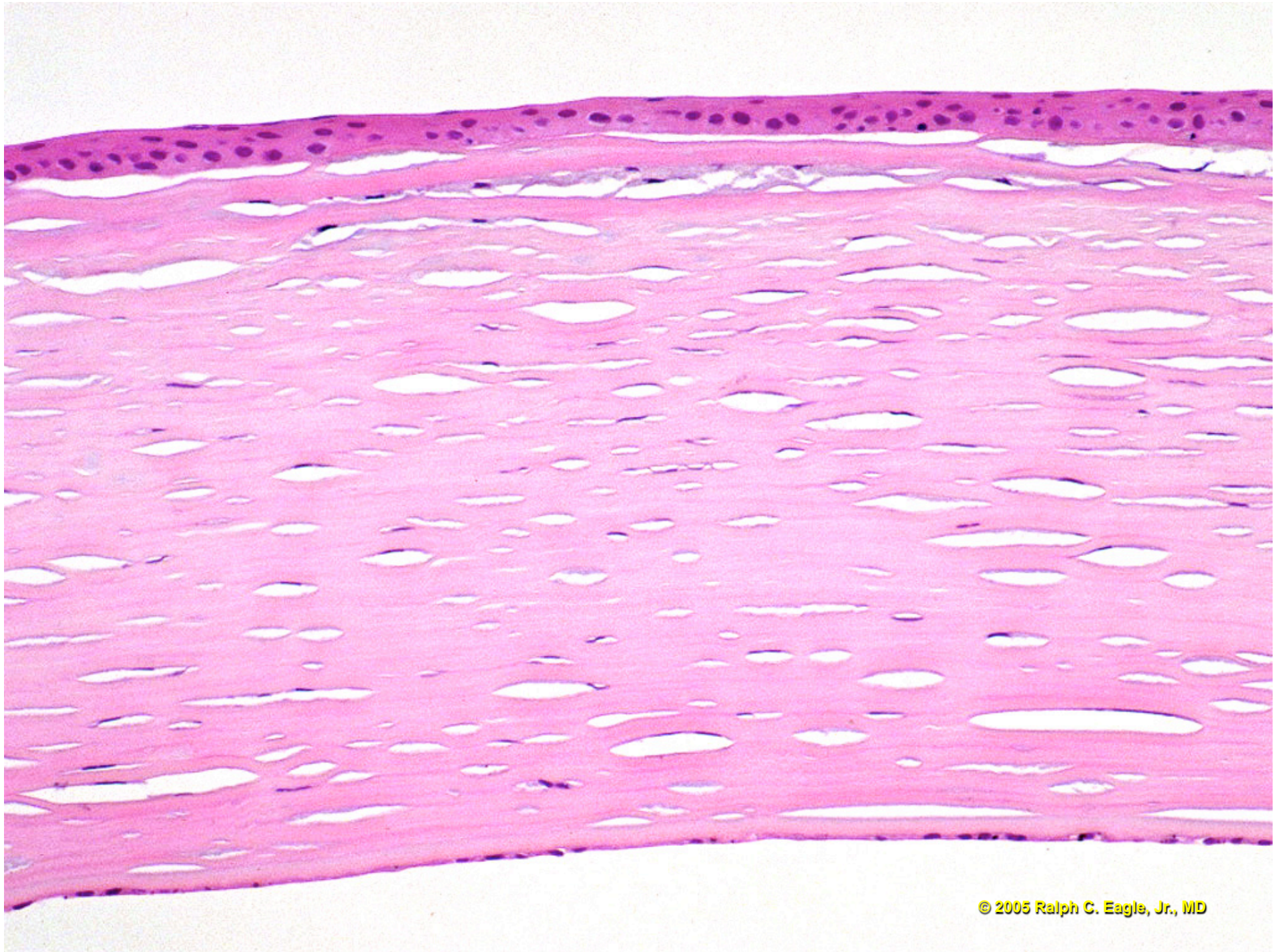
**“sawtoothing” of corneal epithelium**

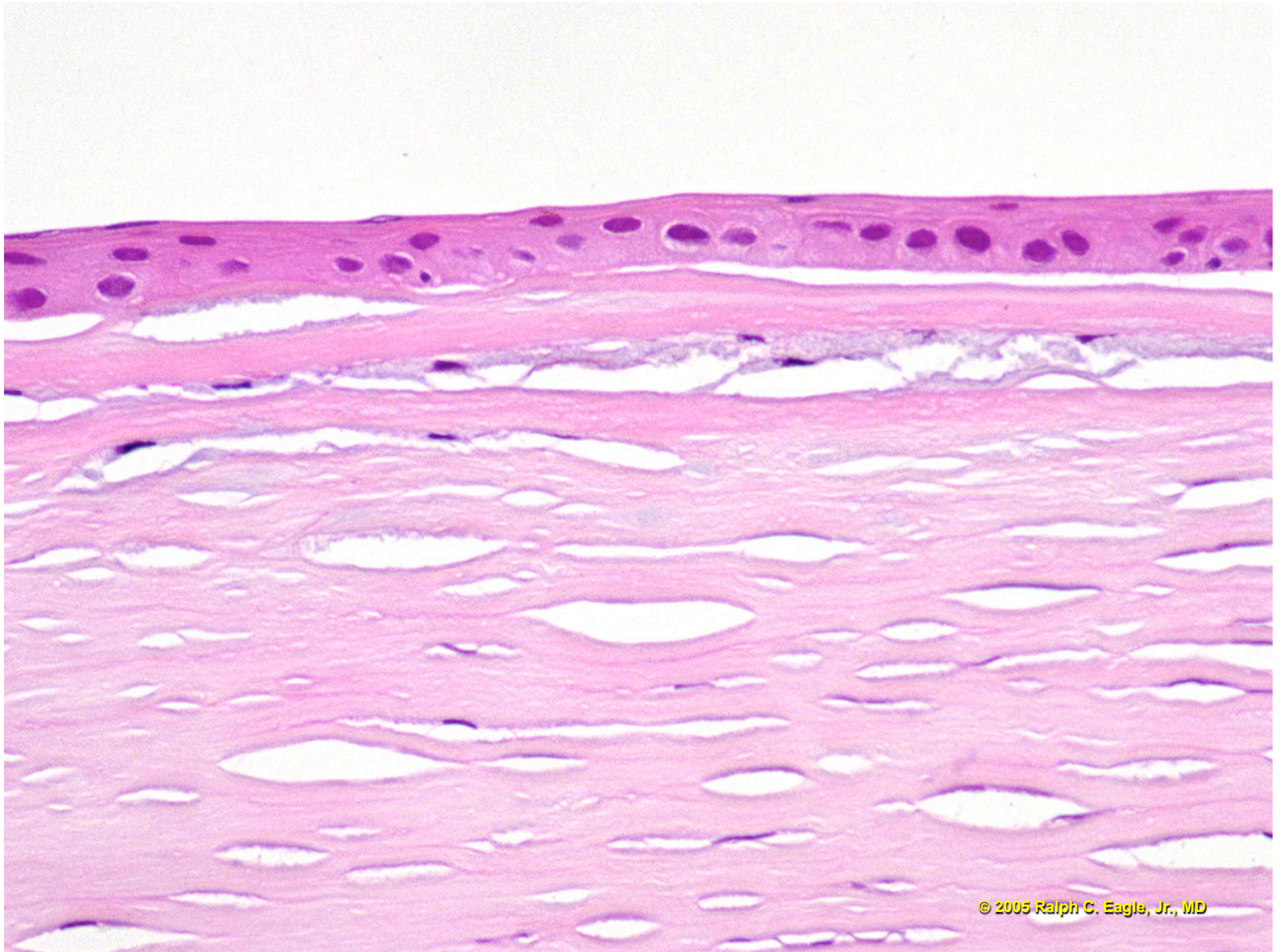
**Lamellated pannus with bands of eosinophilic crystalloids**

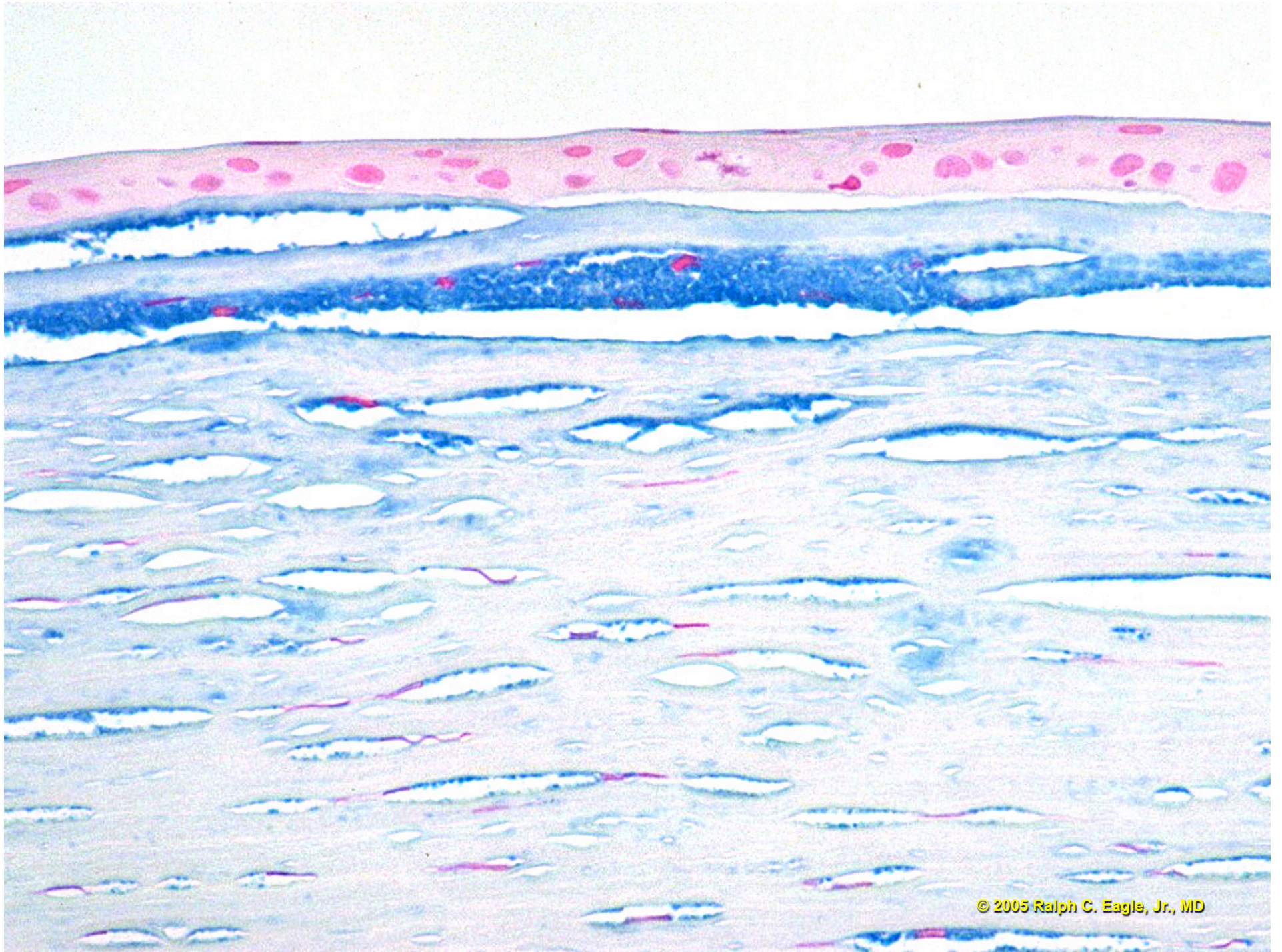
**Bowman’s membrane usually destroyed**


**Reis-Bückler’s Dystrophy**











## Macular Dystrophy

Cornea thin or normal thickness

Frothy, mildly basophilic material in cytoplasm of keratinocytes, endothelial cells

Larger free deposits of material in stroma

Material stains positively for acid mucopolysaccharide  
(**alcian blue, colloidal iron**)

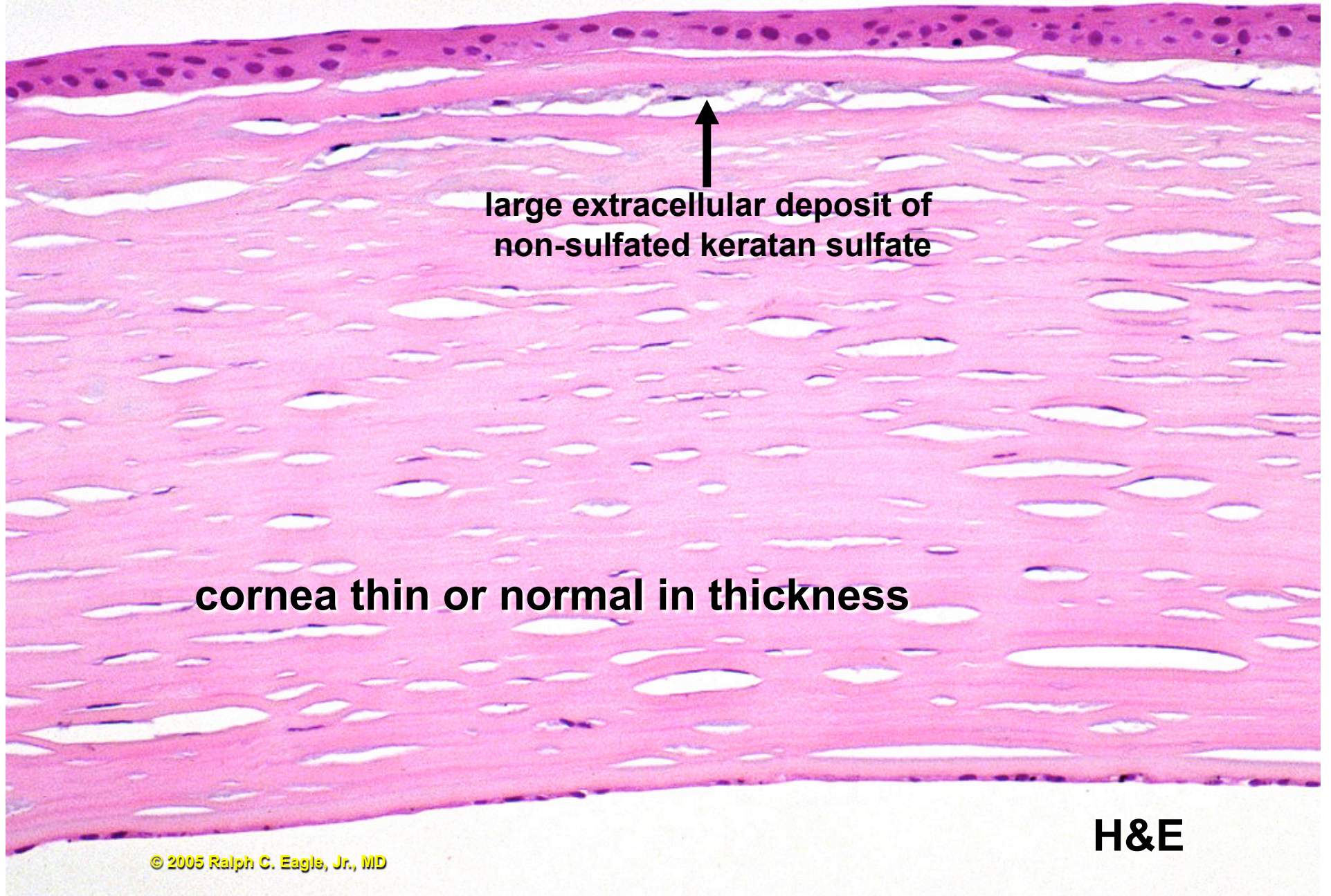
Guttate excrescences may be present on Descemet's membrane

Autosomal recessive

Carbohydrate Sulftransferase Gene 6

Defective N-acetylglucosamine-6-sulfotransferase

# Macular Dystrophy

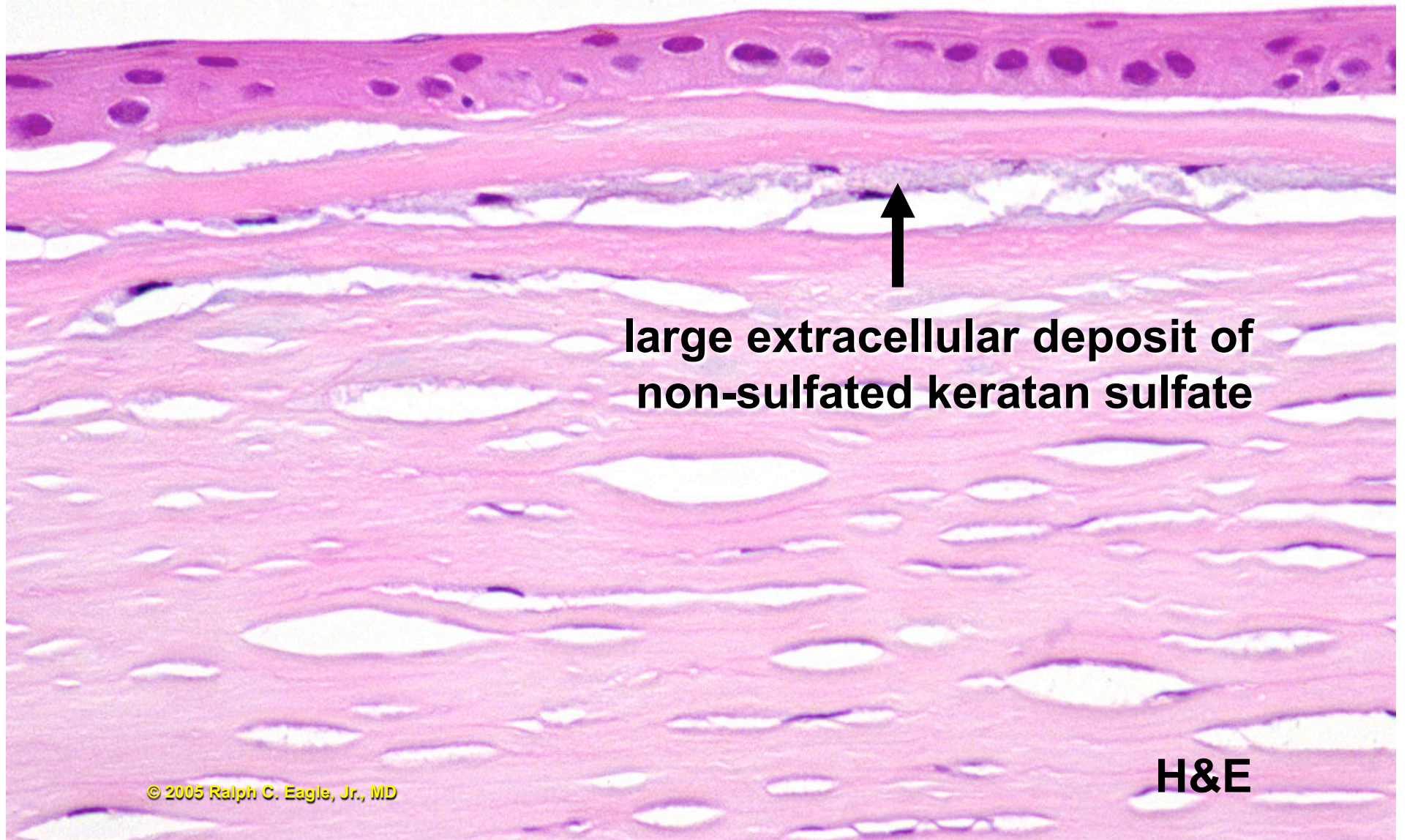


large extracellular deposit of  
non-sulfated keratan sulfate

cornea thin or normal in thickness

H&E

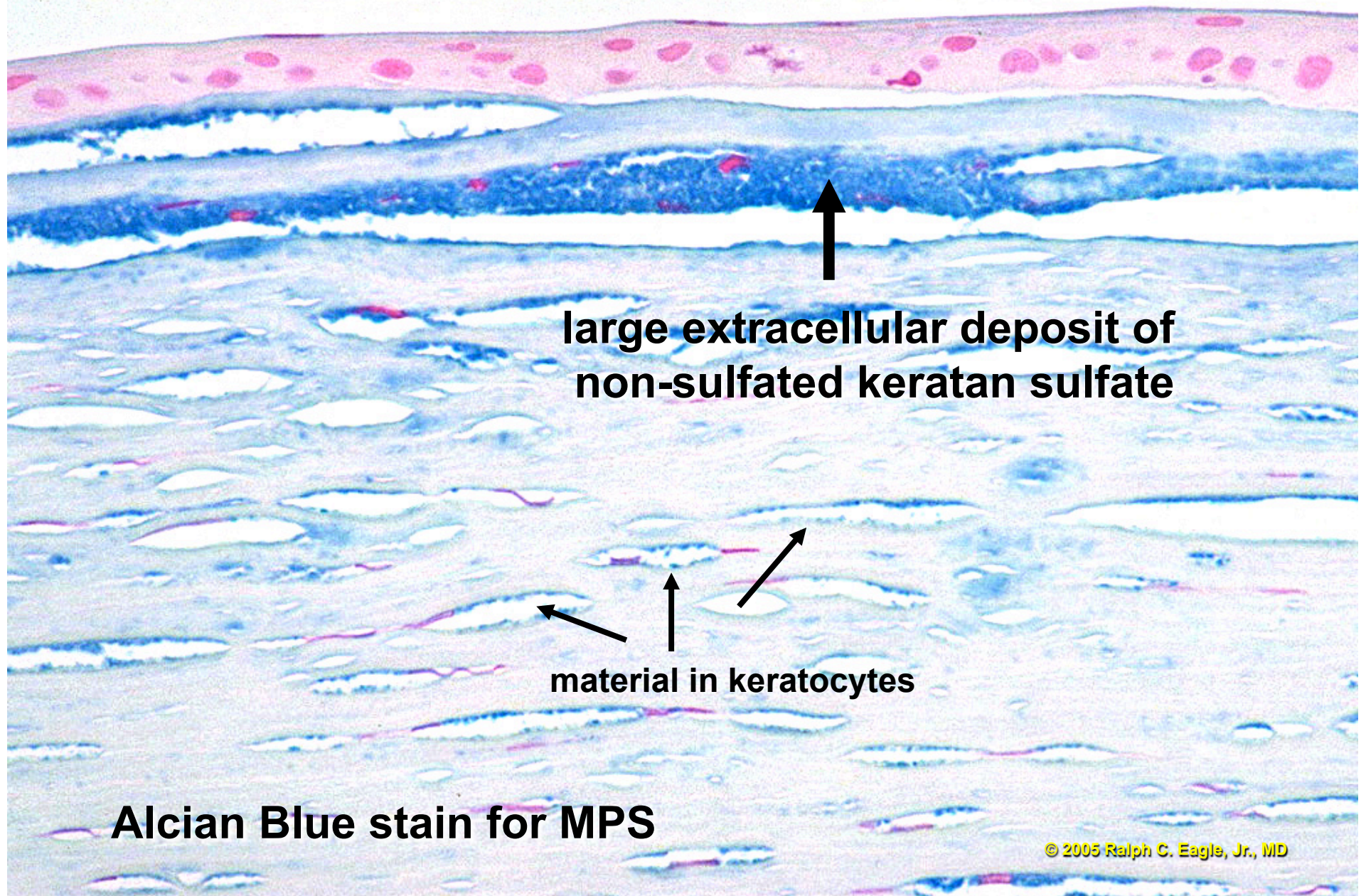
# Macular Dystrophy



large extracellular deposit of  
non-sulfated keratan sulfate

H&E

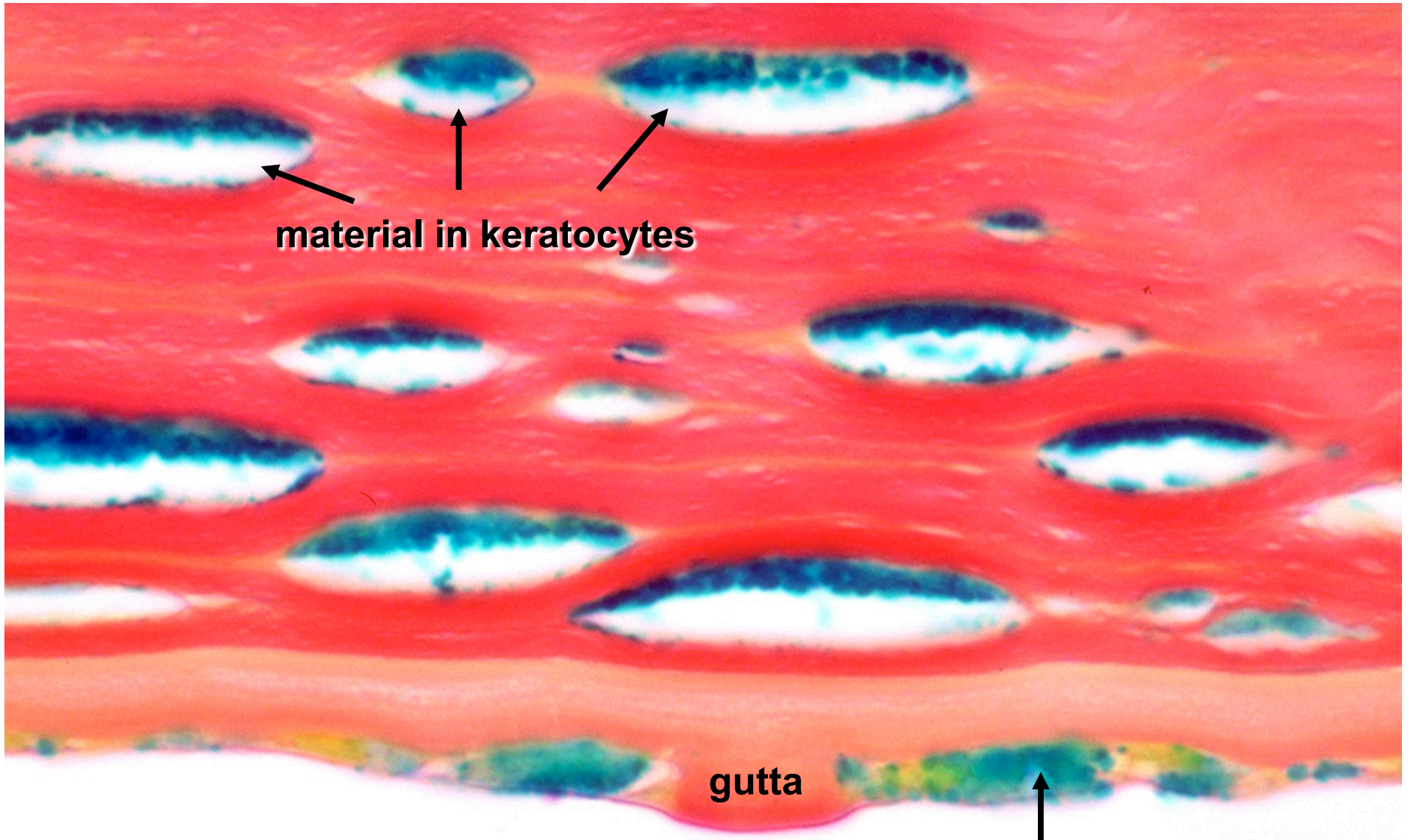
# Macular Dystrophy



large extracellular deposit of  
non-sulfated keratan sulfate

material in keratocytes

Alcian Blue stain for MPS



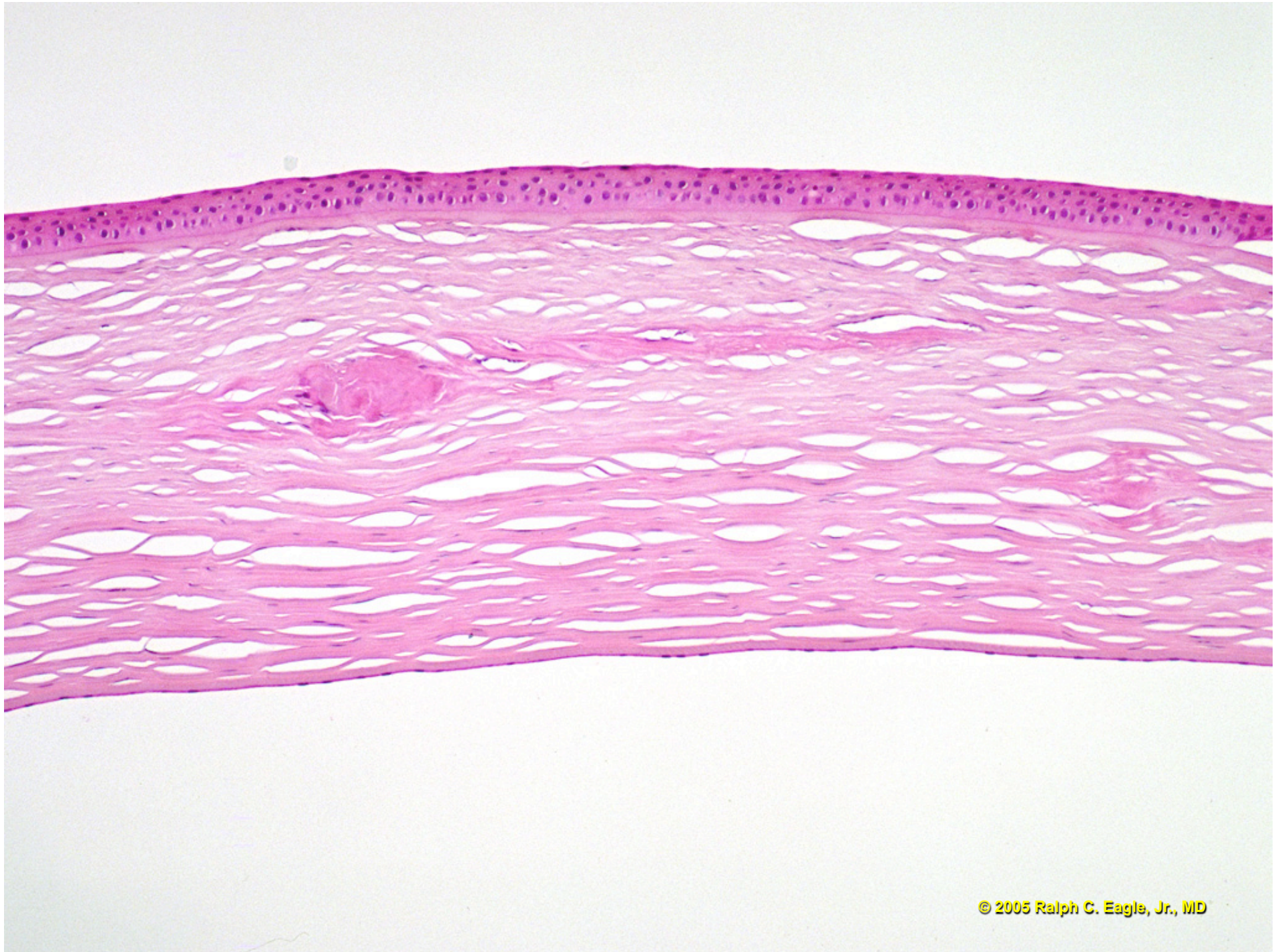
material in keratocytes

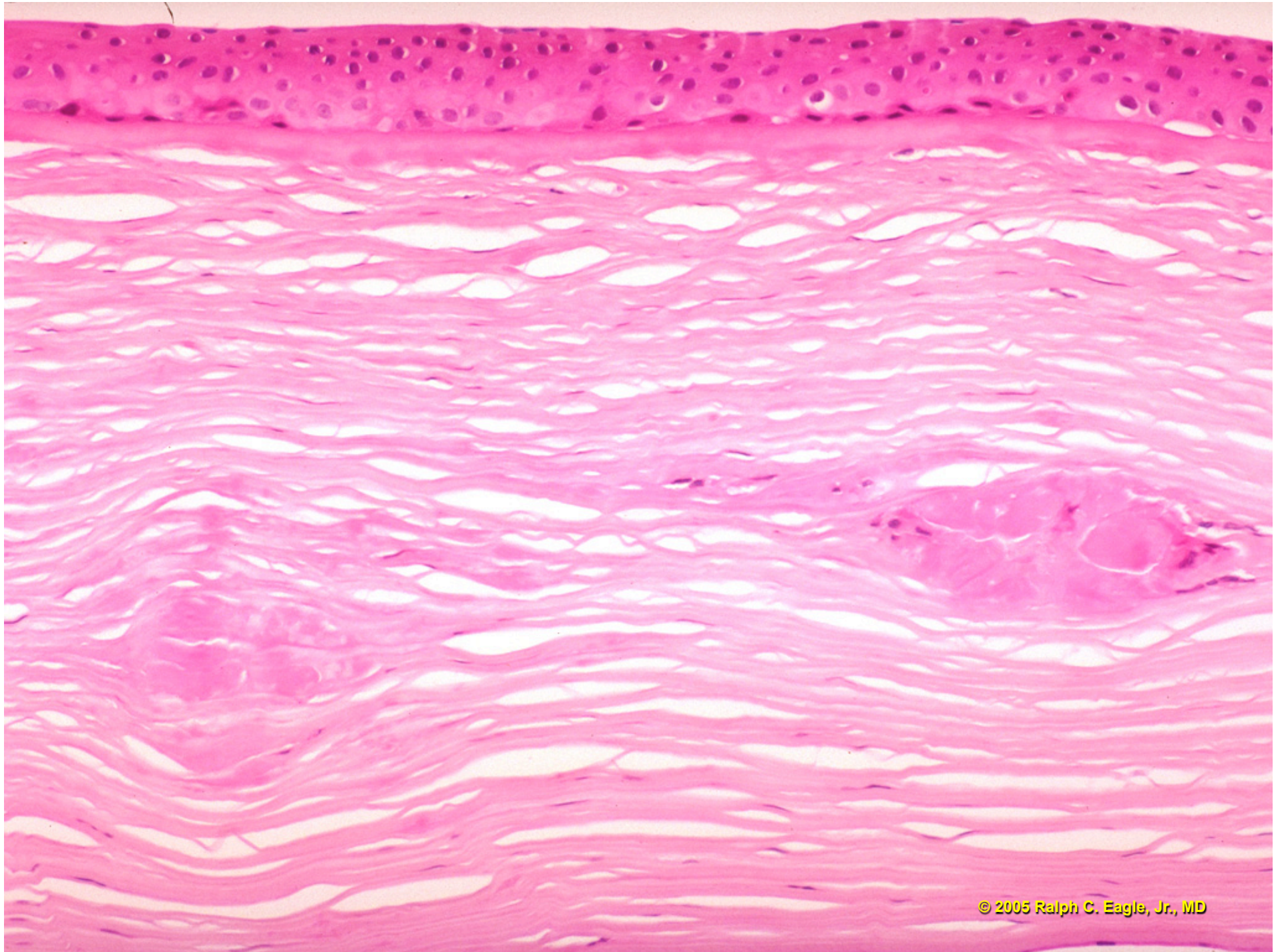
gutta

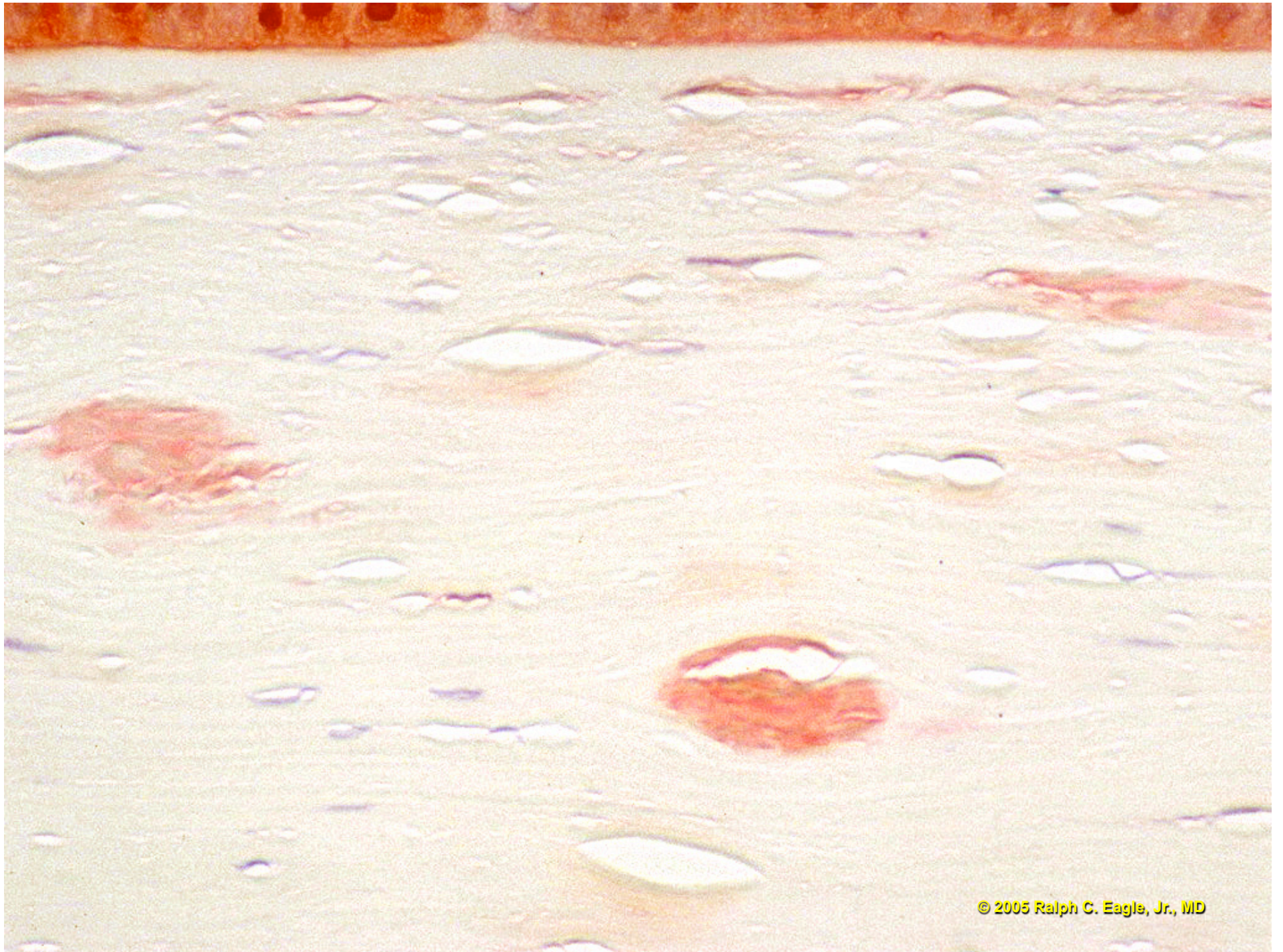
material in  
endothelium


# Macular Dystrophy

colloidal iron stain for MPS





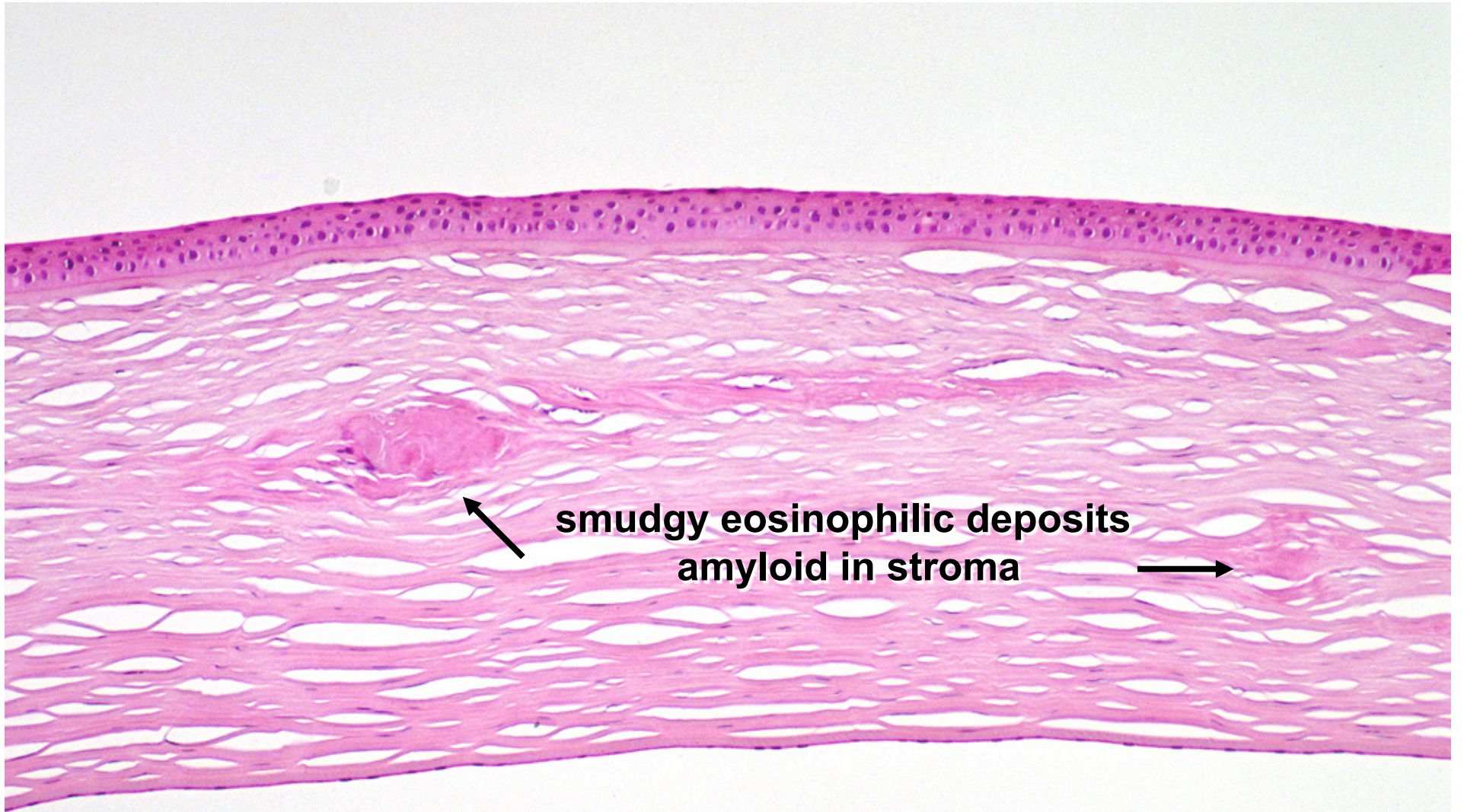




# **Lattice Dystrophy**

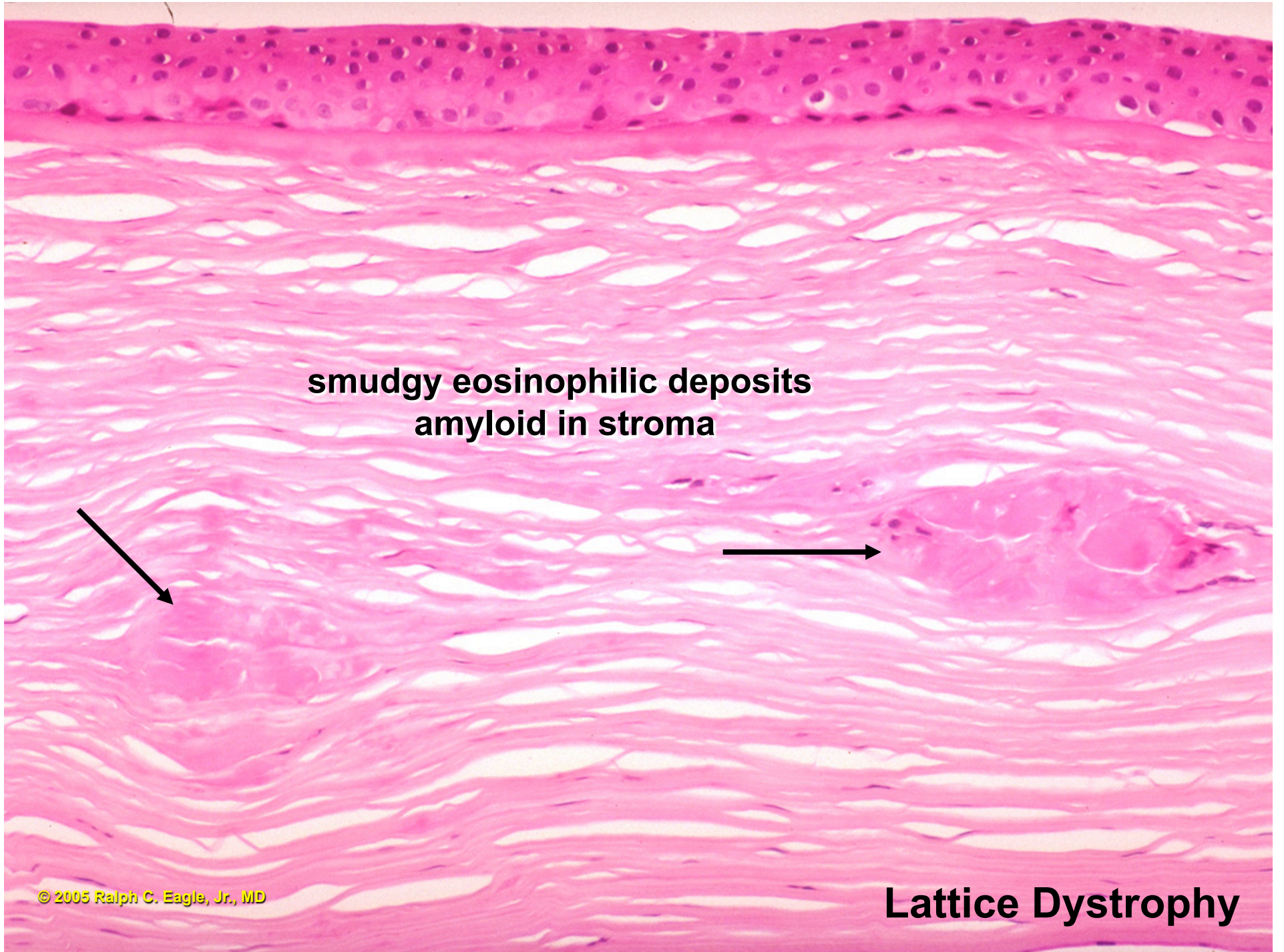
Subepithelial and oval intrastromal deposits of amyloid  
Deposits stain positively with Congo red stain  
Apple green birefringence with polarization microscopy

Autosomal Dominant (type I)  
TGFBI gene (BigH3)



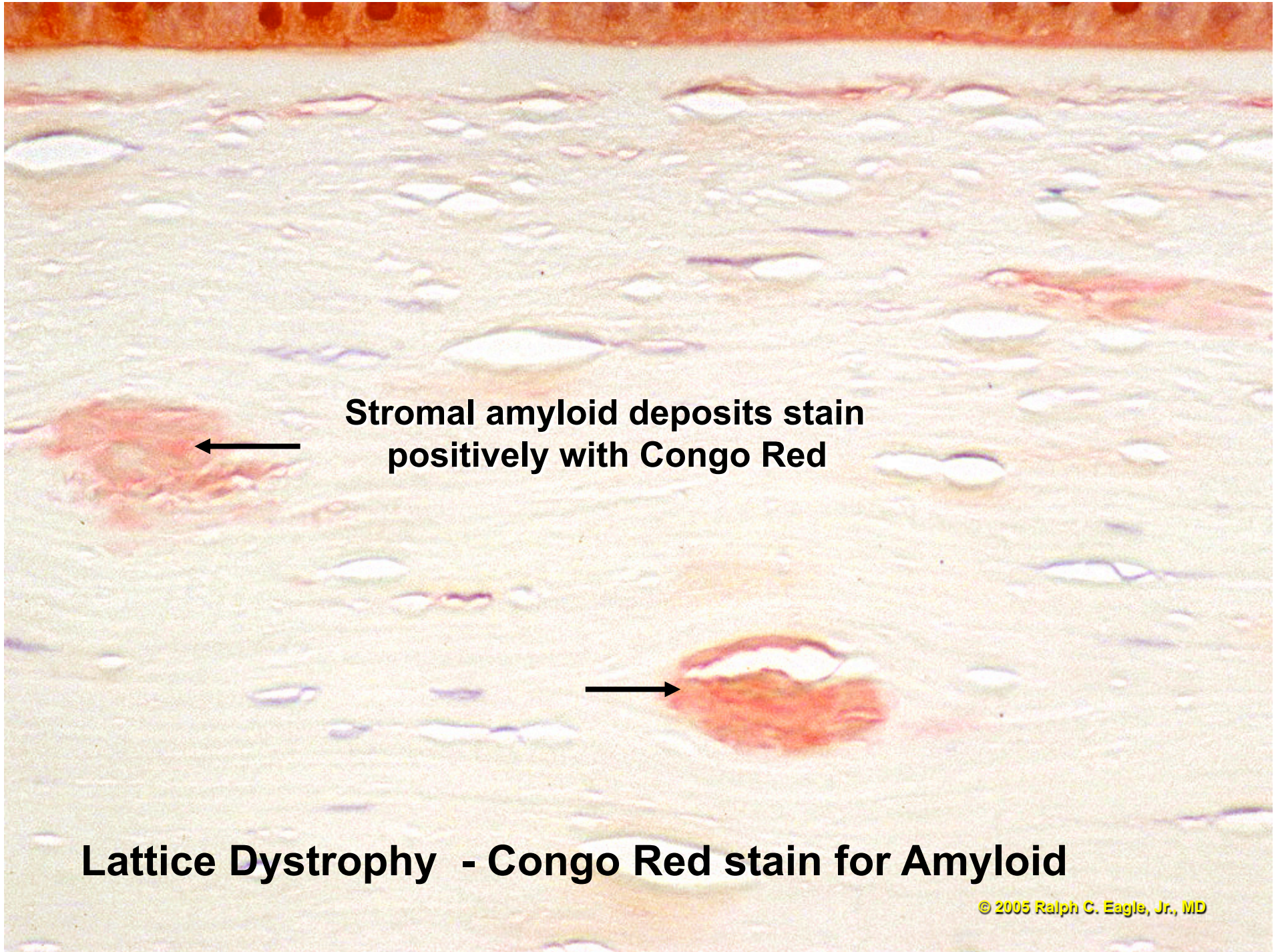
smudgy eosinophilic deposits  
amyloid in stroma

# Lattice Dystrophy



**smudgy eosinophilic deposits  
amyloid in stroma**

**Lattice Dystrophy**



**Stromal amyloid deposits stain positively with Congo Red**

**Lattice Dystrophy - Congo Red stain for Amyloid**

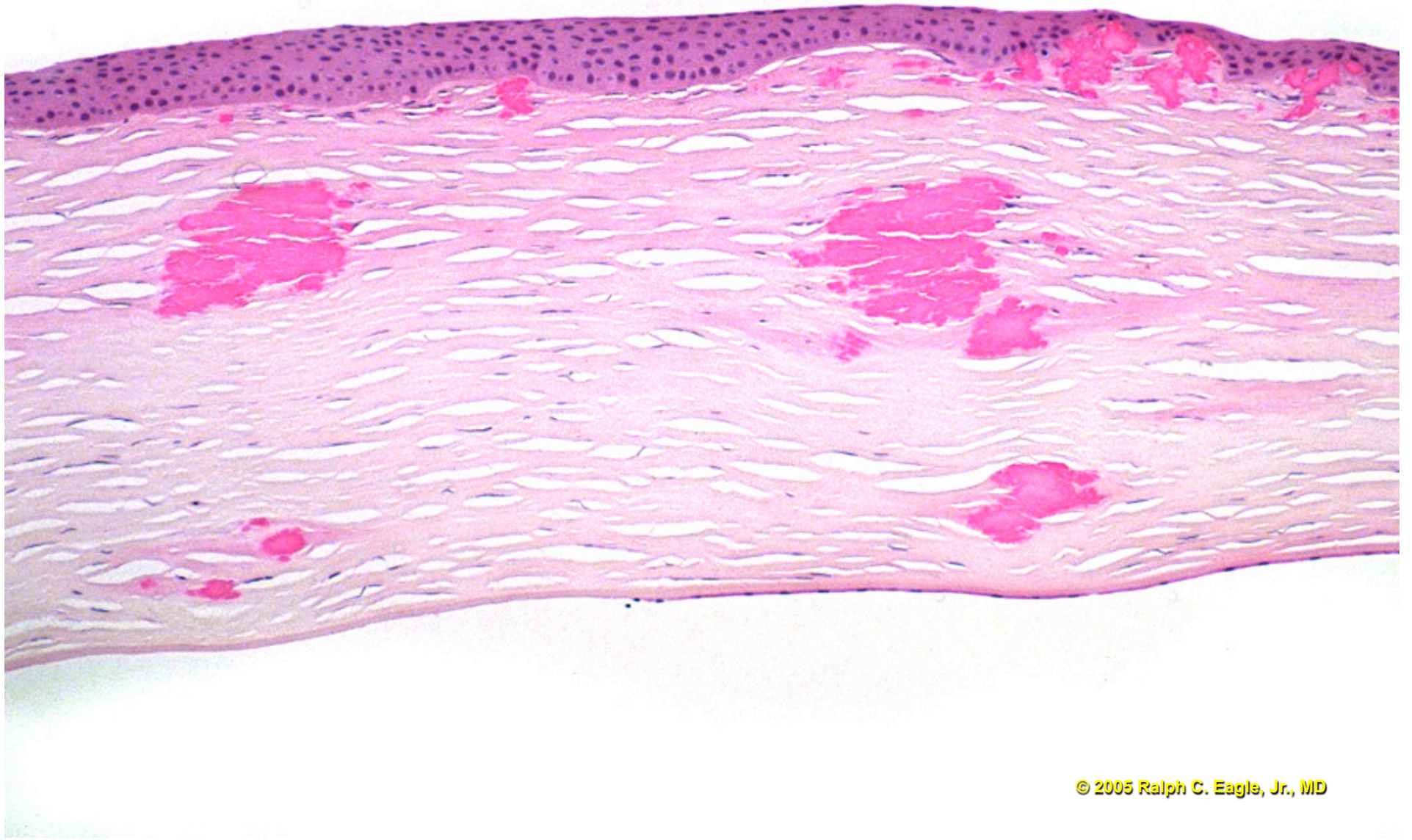

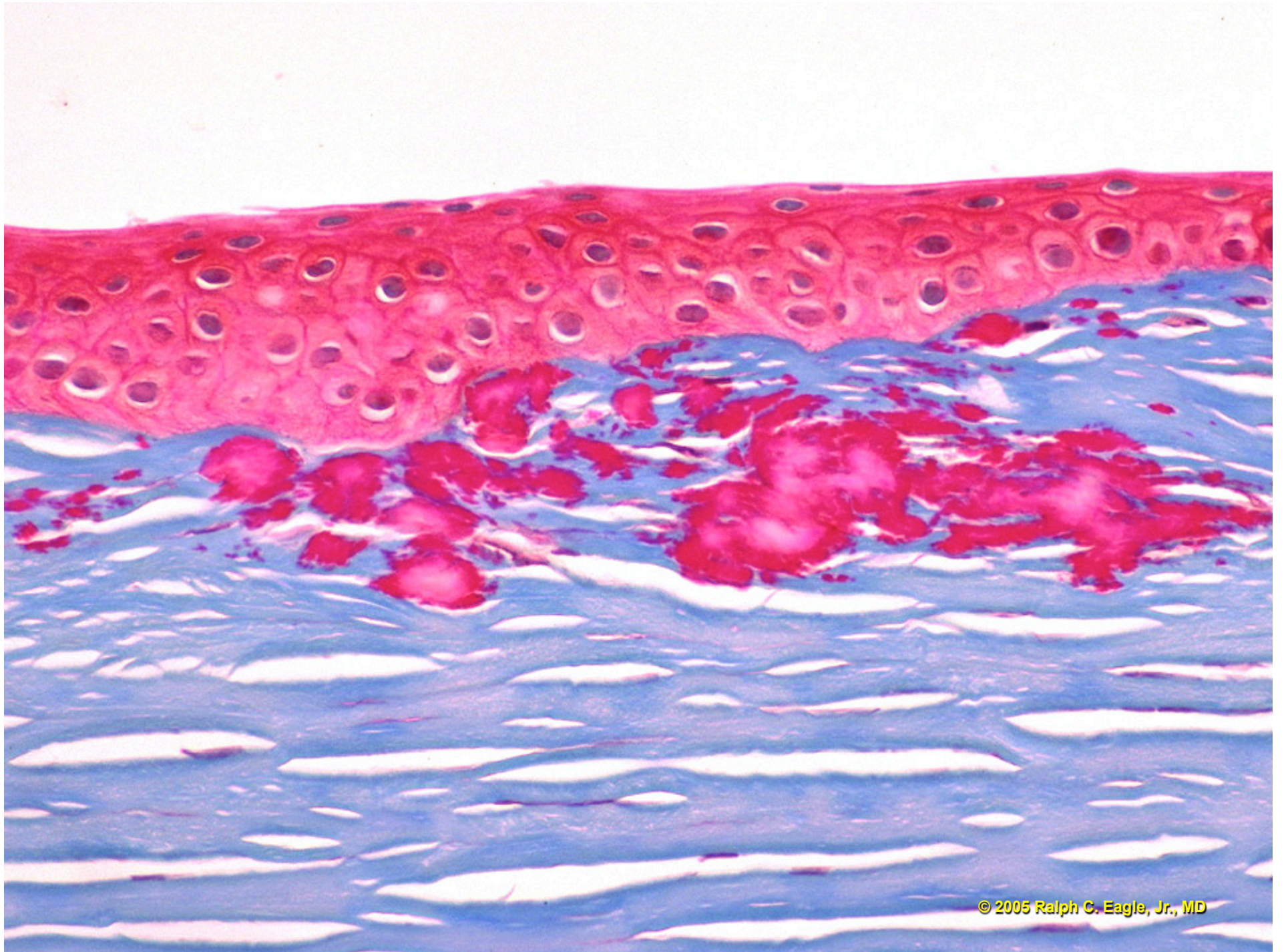
subepithelial amyloid

The image shows a microscopic view of tissue stained with Congo red. Under polarized light, the amyloid deposits exhibit a characteristic apple green birefringence. The deposits are seen as bright green, wavy, and somewhat irregular structures against a dark blue background. One prominent deposit is located in the lower right quadrant, and another is in the lower left. A horizontal arrow points to the left, and a vertical arrow points upwards, both indicating the location of subepithelial amyloid deposits.

Apple green birefringence  
of amyloid deposits with  
polarized light

**Lattice Dystrophy - Congo Red stain for Amyloid**





# Granular Dystrophy

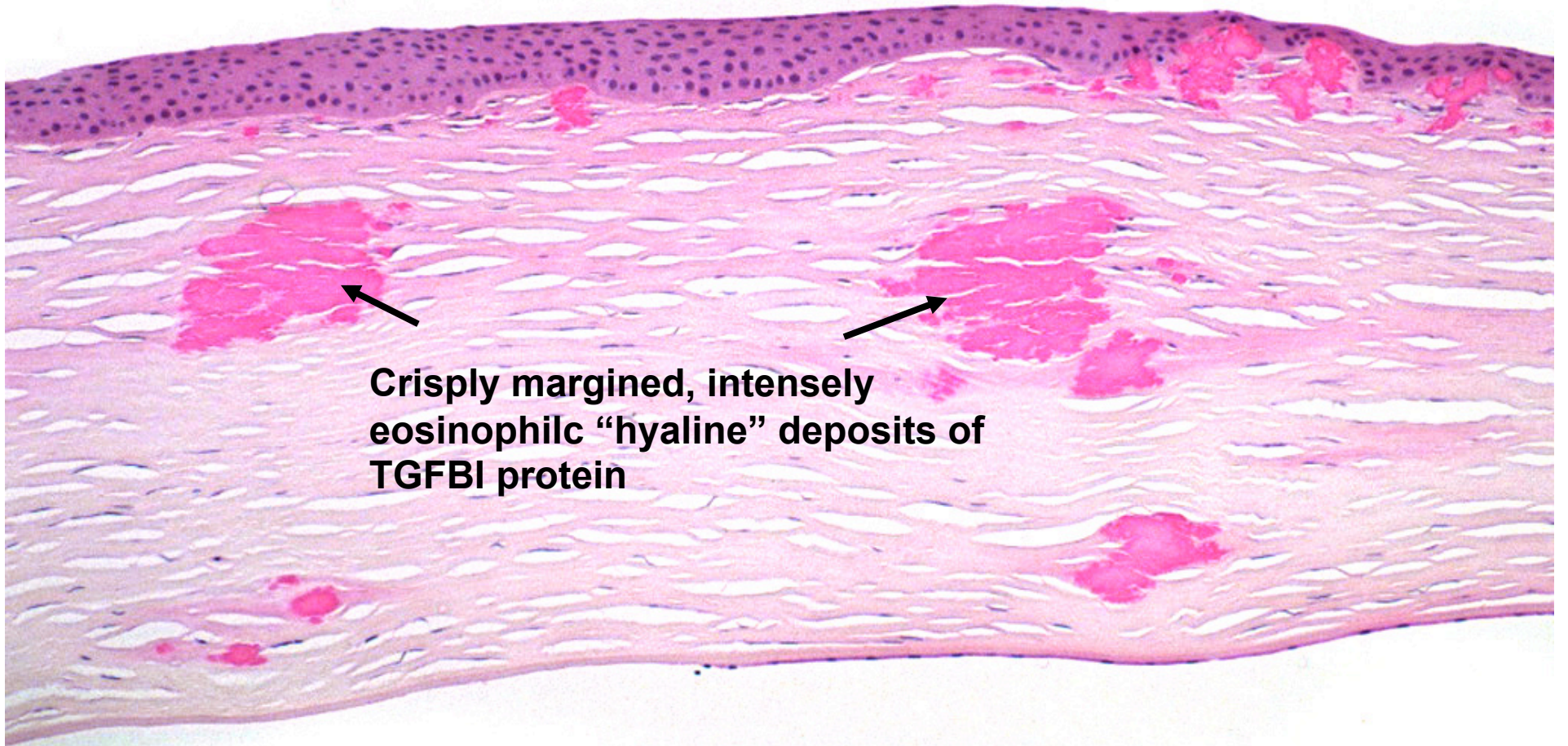
Irregular intensely eosinophilic "rock candy" deposits in stroma

Deposits stain red with Masson trichrome

Deposits are PAS negative, less birefringent than normal stroma

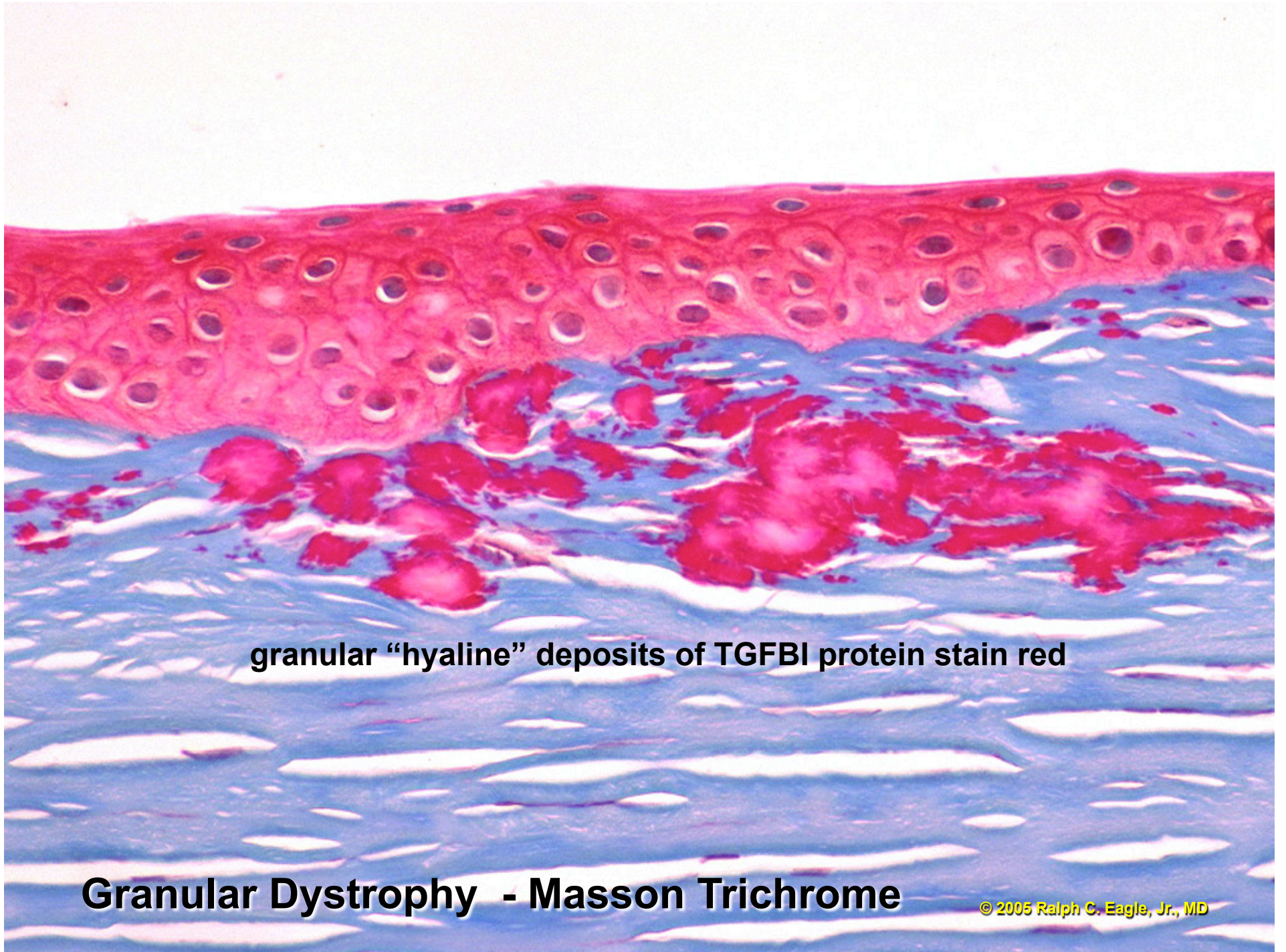
Autosomal dominant

TGFBI gene (BigH3)



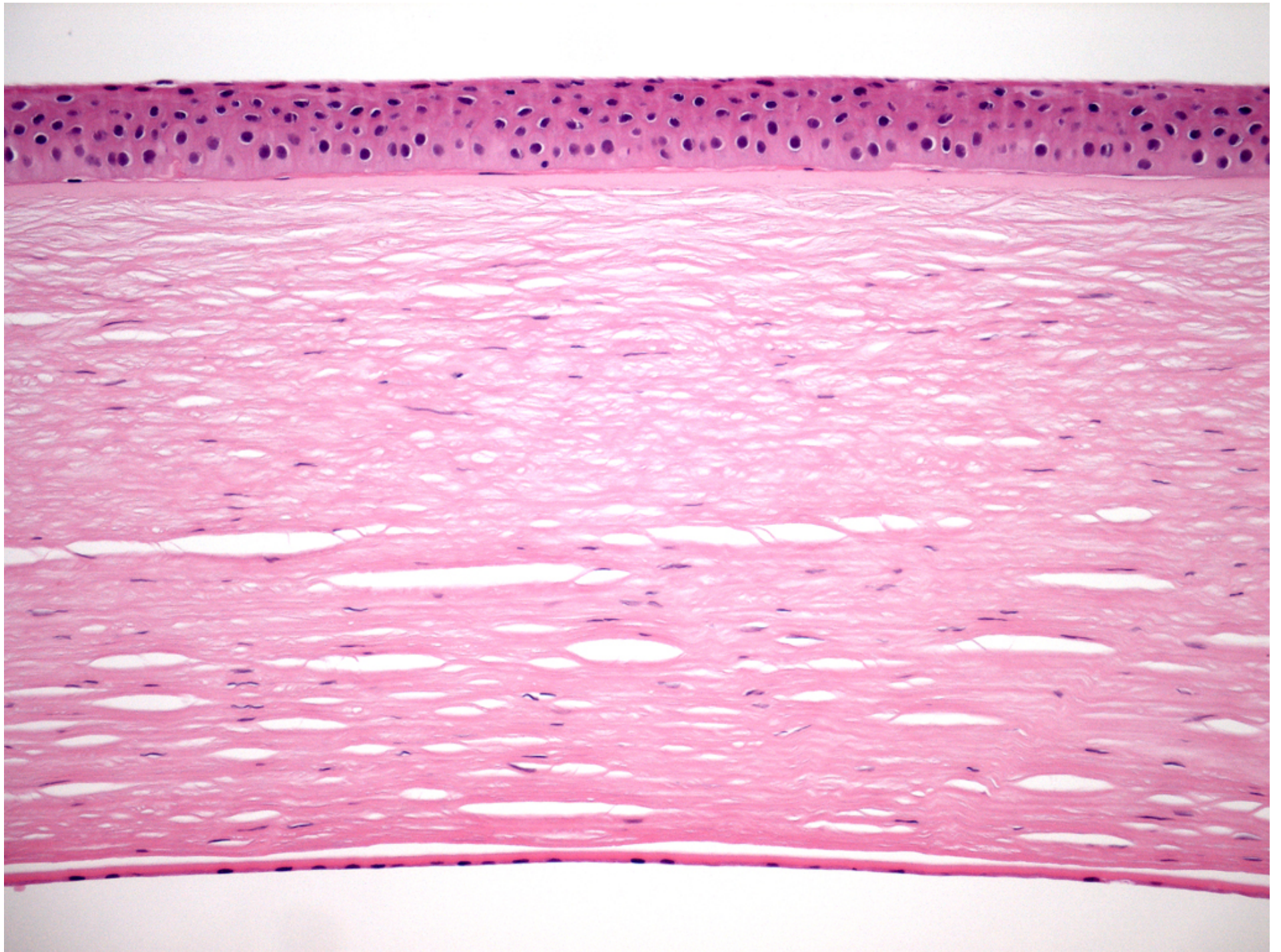
**Crisply margined, intensely eosinophilic "hyaline" deposits of TGFBI protein**

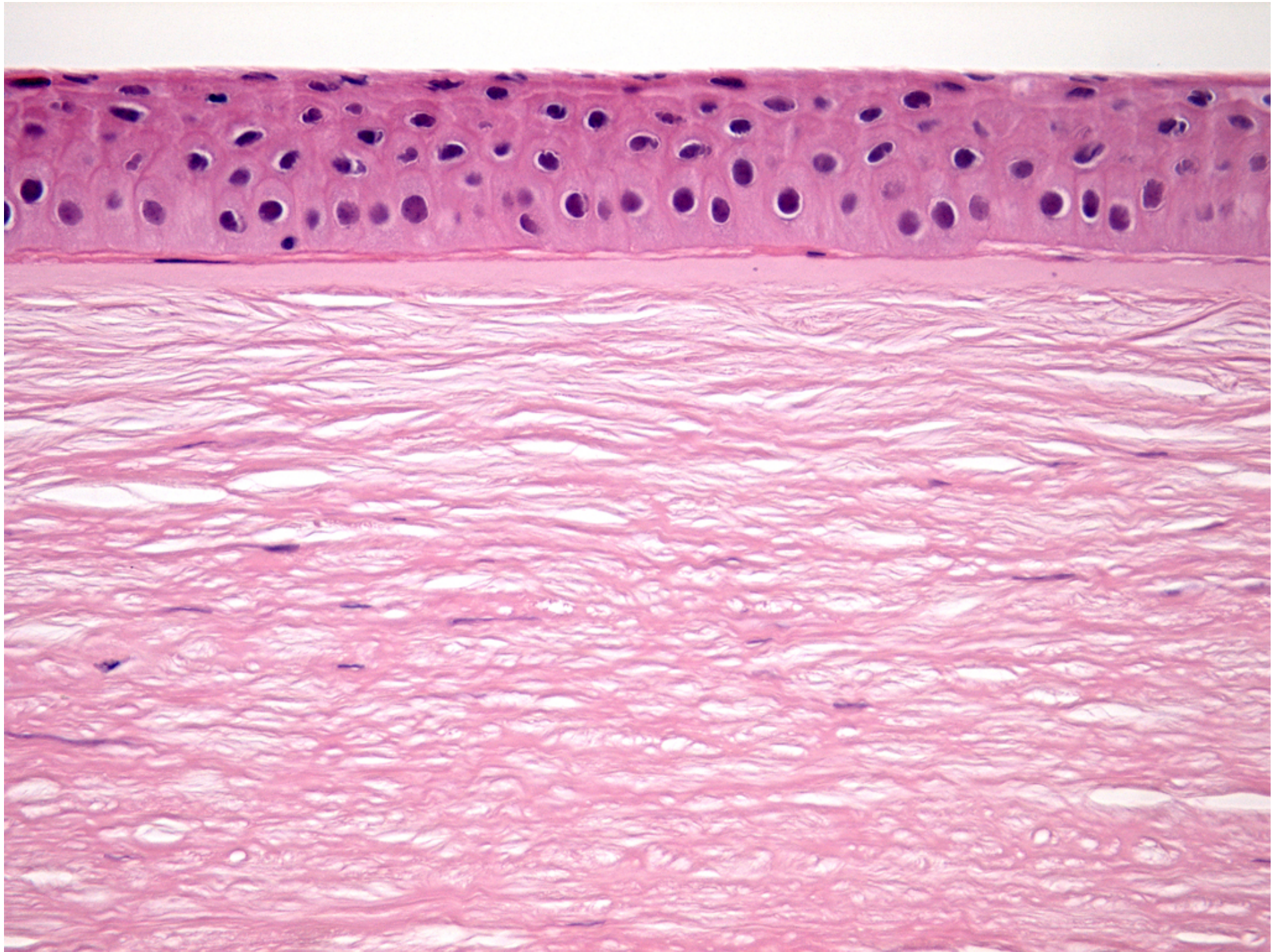
## **Granular Dystrophy**



**granular “hyaline” deposits of TGFBI protein stain red**

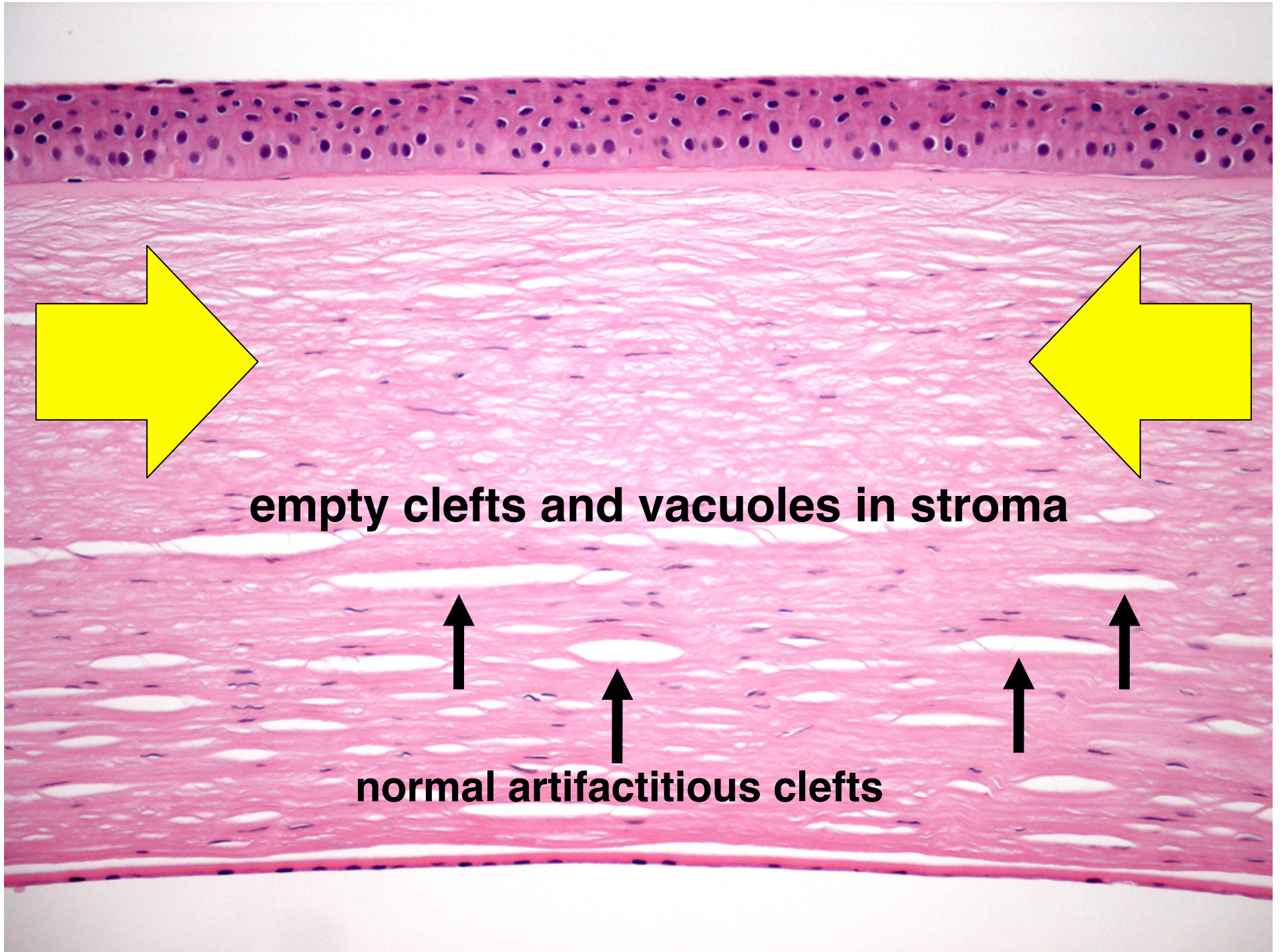
## **Granular Dystrophy - Masson Trichrome**





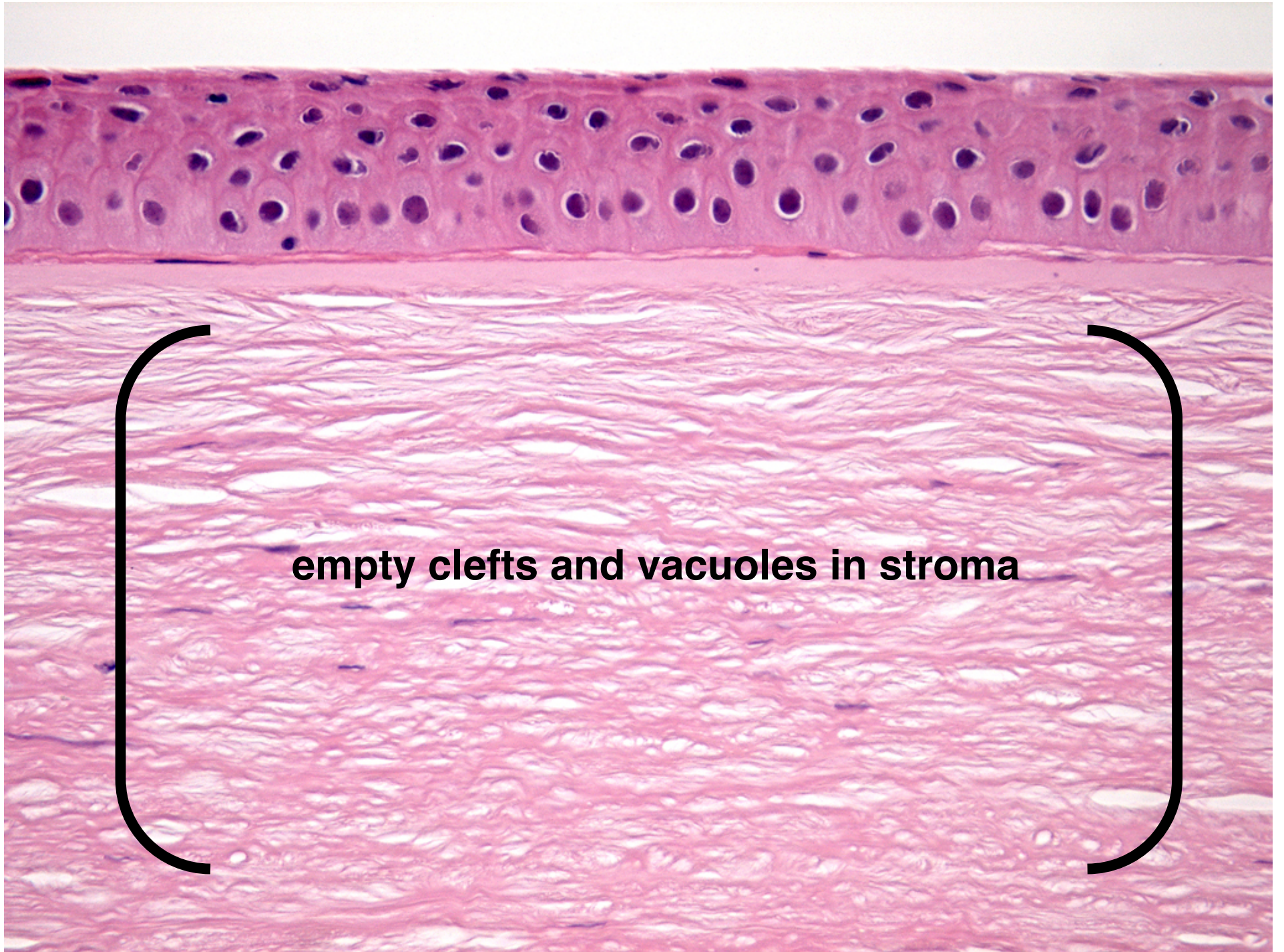
# **Schnyder's Crystalline Dystrophy**

**Empty clefts and vacuoles in corneal stroma  
Lipid dissolved during processing  
(crystals are not present in all cases)**

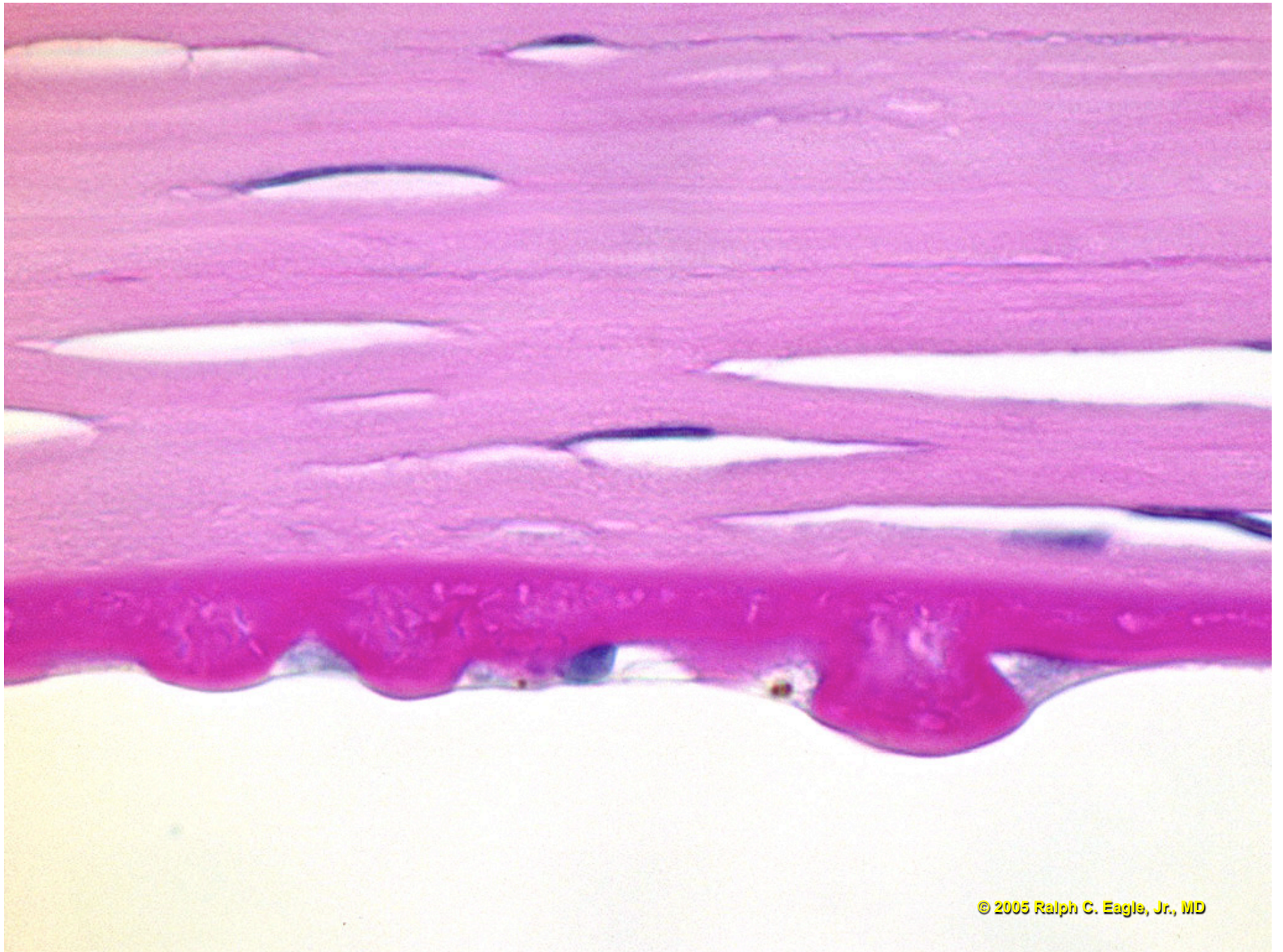


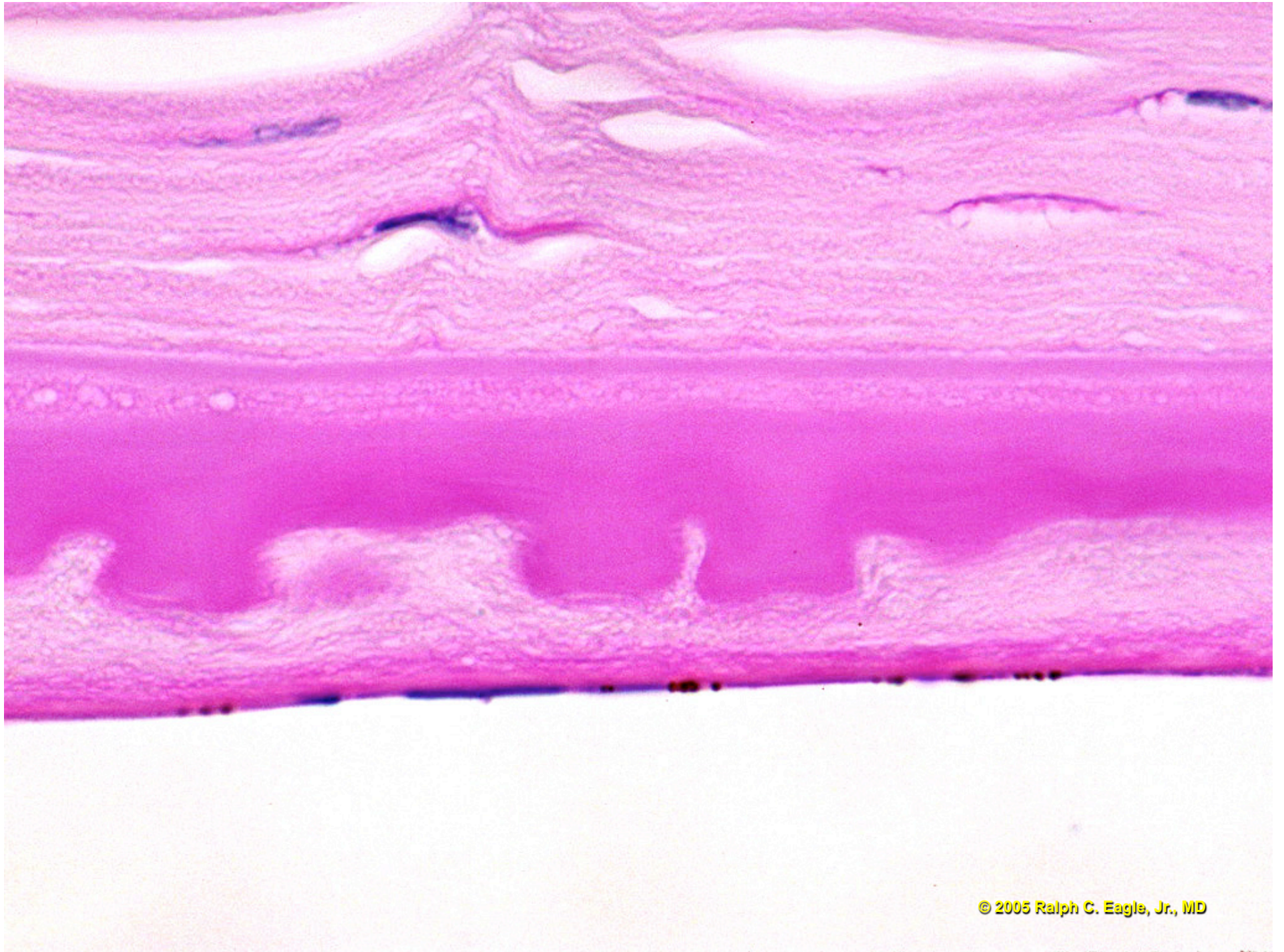
**empty clefts and vacuoles in stroma**

**normal artifactitious clefts**



**empty clefts and vacuoles in stroma**





## **Fuchs' Dystrophy**

Epithelial bullae, degenerative pannus in late cases

Thickened edematous stroma (cotton candy appearance)

Anvil-shaped guttate excrescences on Descemet's membrane

Descemet's membrane thickened, often multilaminar

Guttae may be "buried"

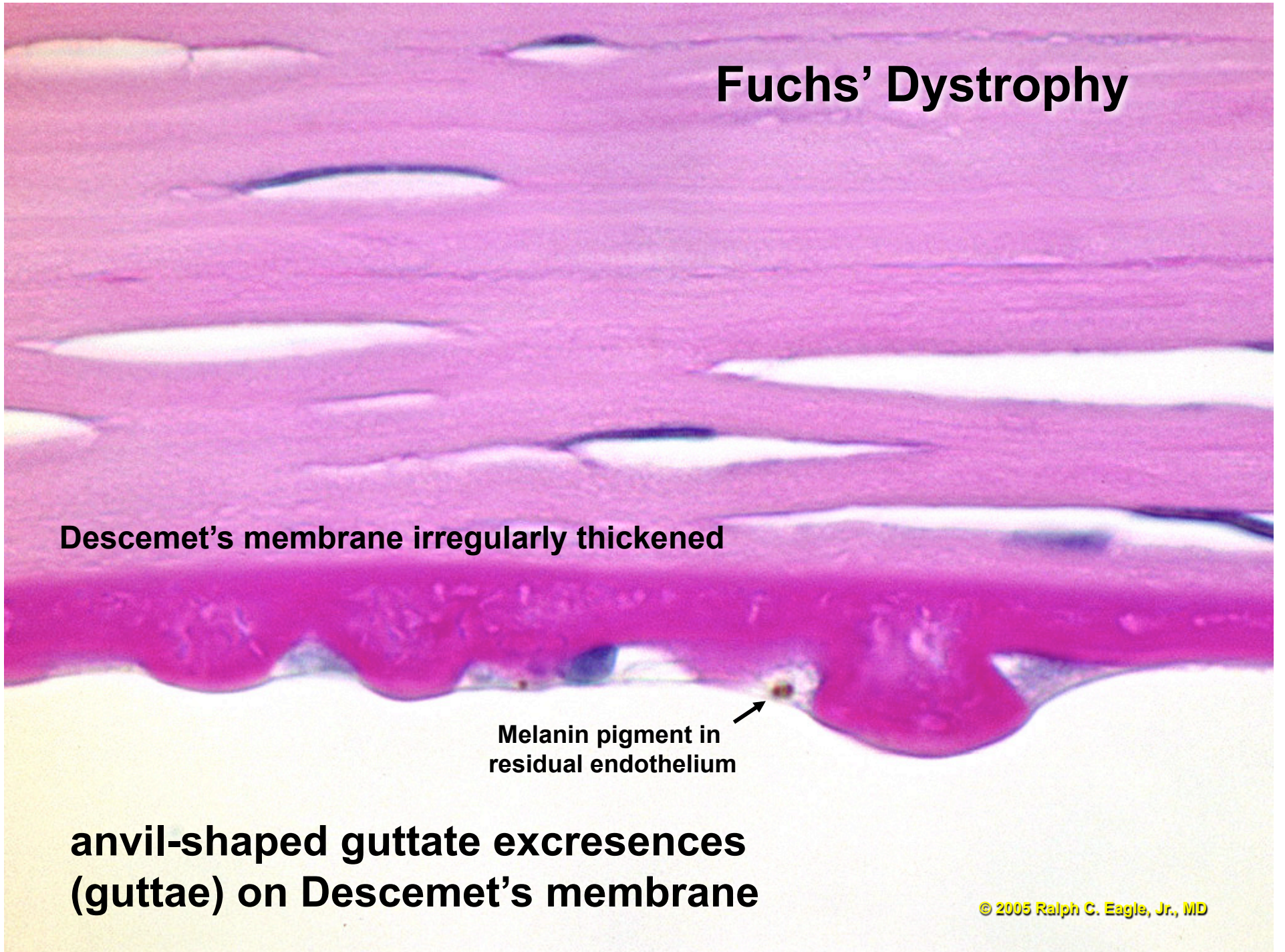
Endothelium atrophic, cells often contain pigment granules

# Fuchs' Dystrophy

Descemet's membrane irregularly thickened

Melanin pigment in residual endothelium

anvil-shaped guttate excrescences (guttae) on Descemet's membrane

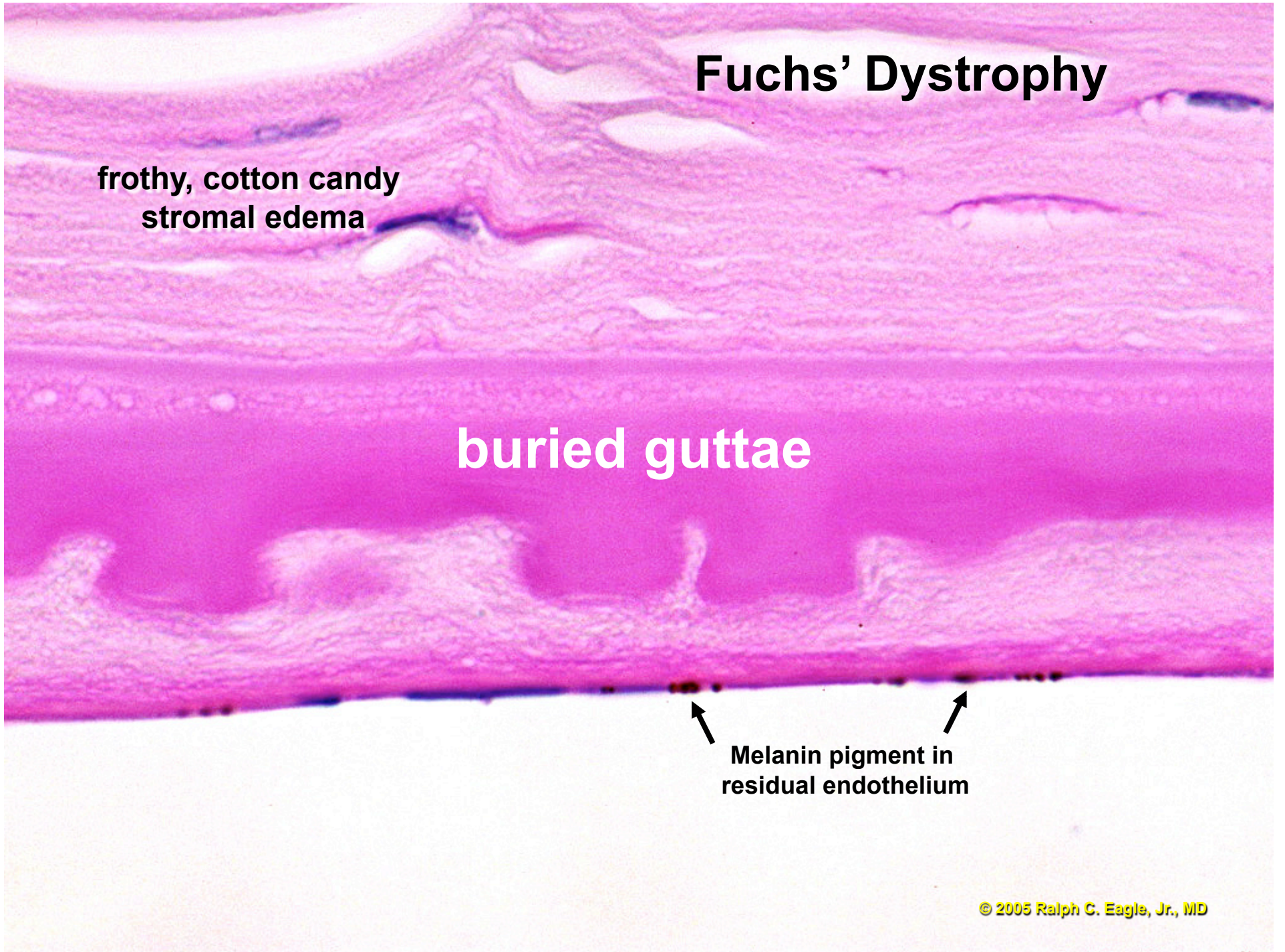


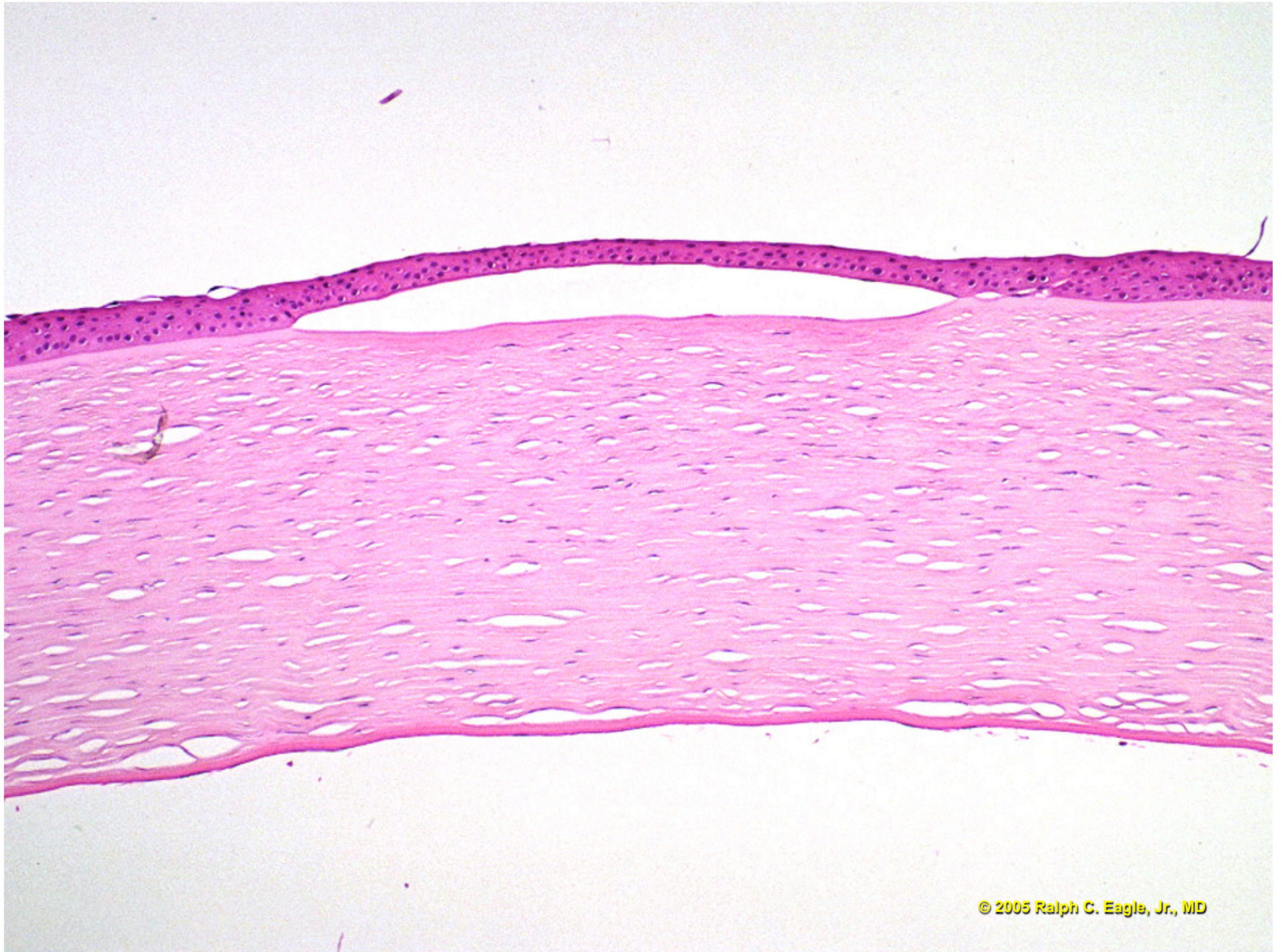# Fuchs' Dystrophy

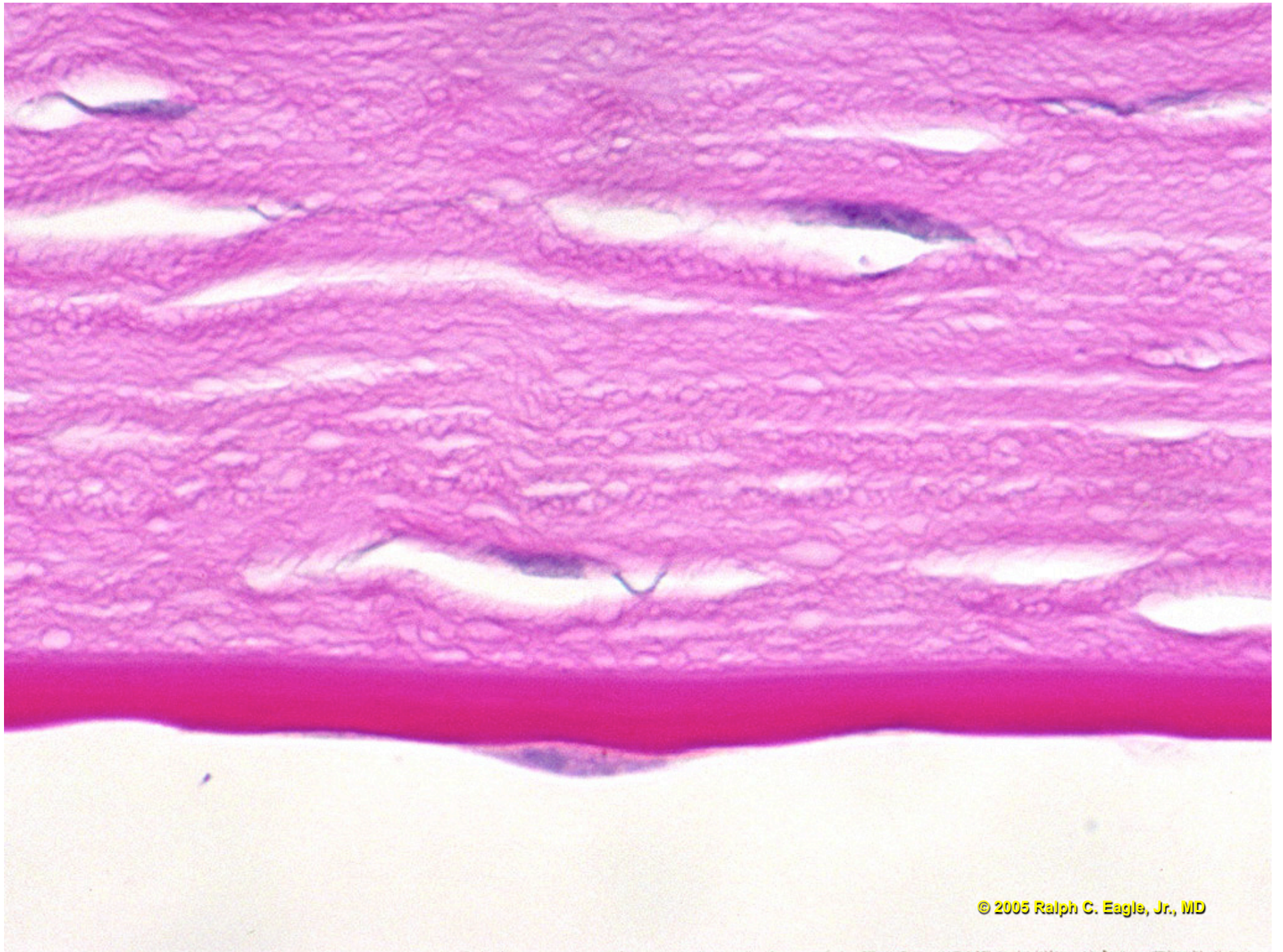
frothy, cotton candy  
stromal edema

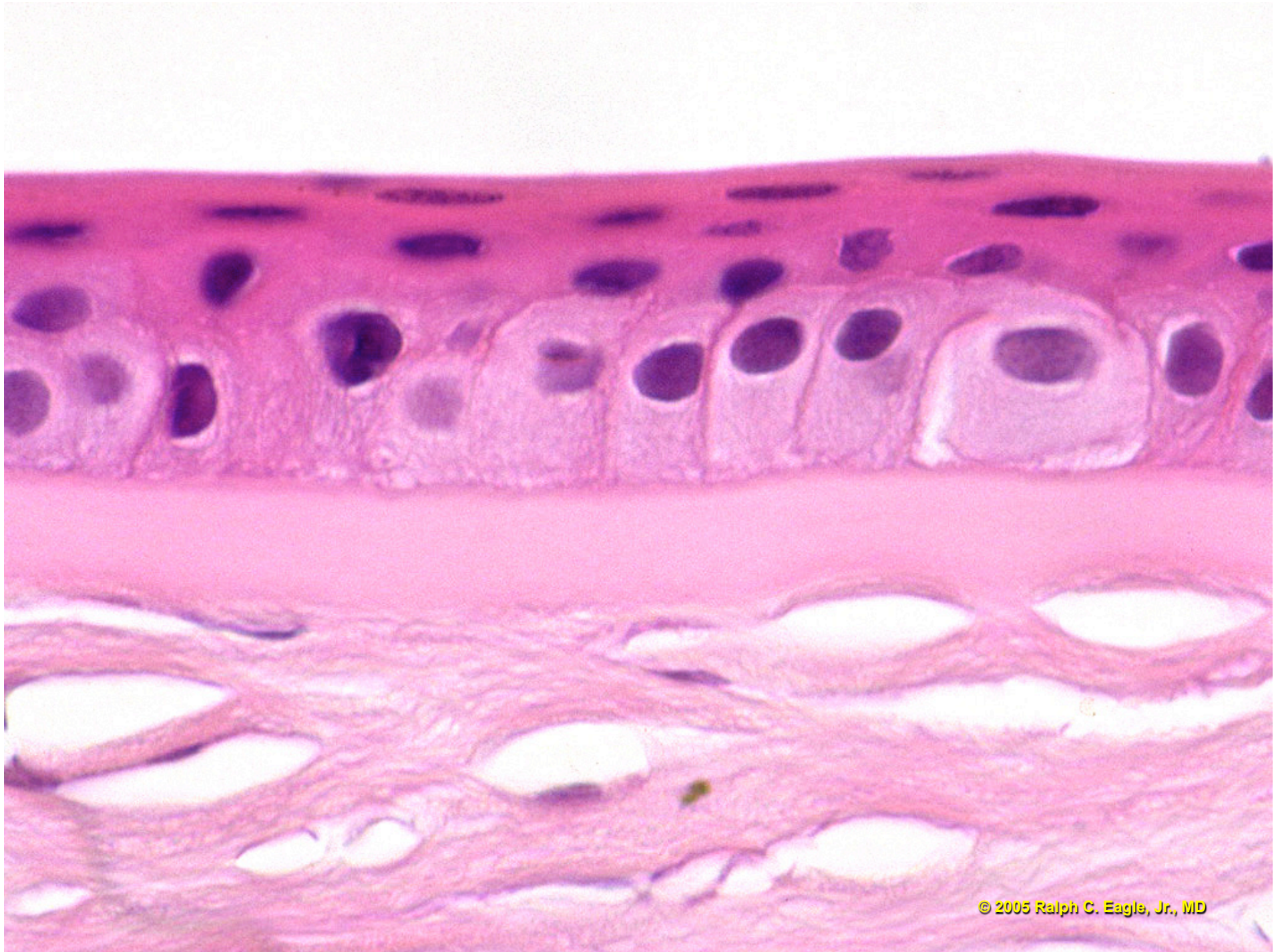buried guttae

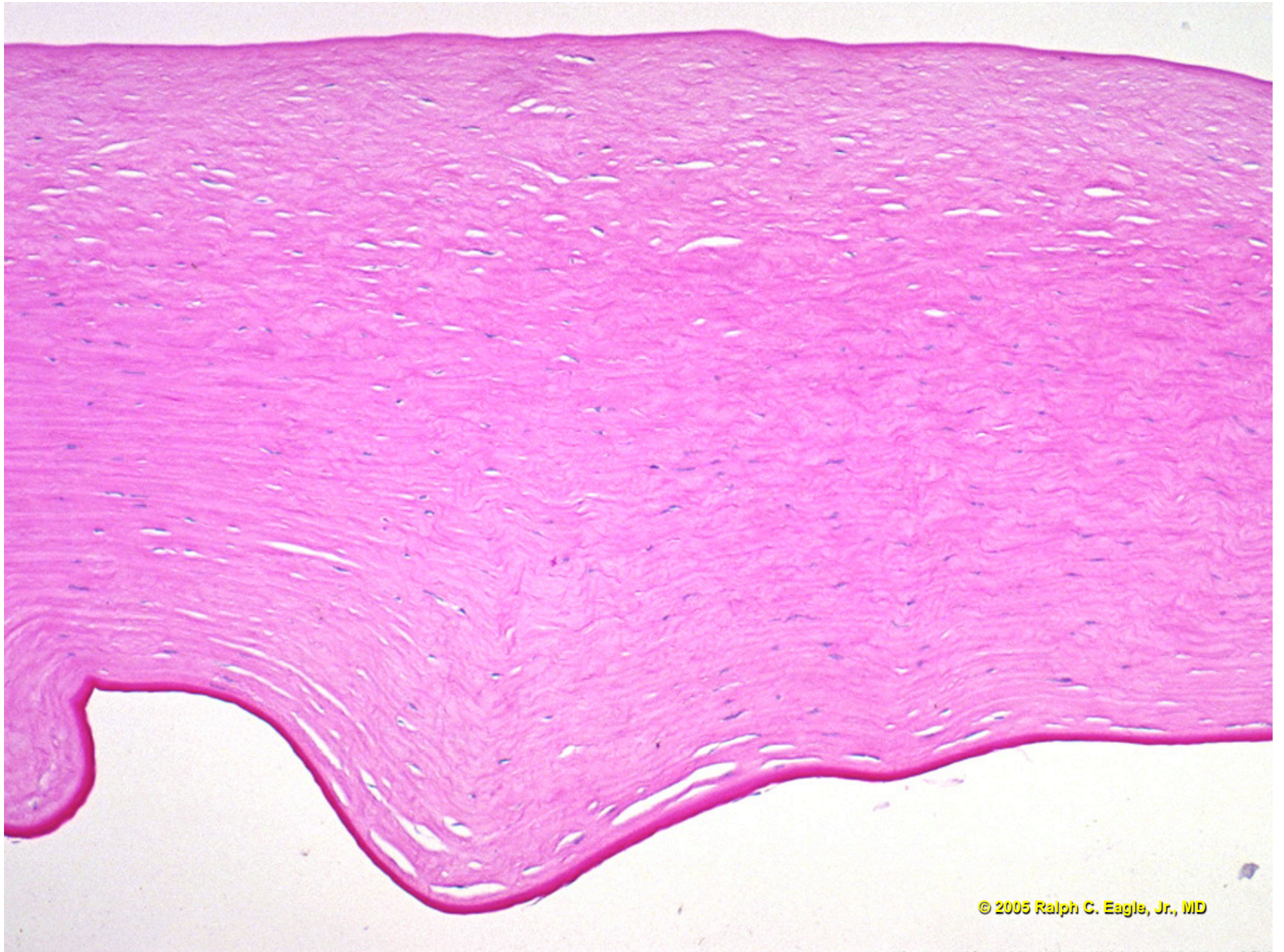Melanin pigment in  
residual endothelium











## **Pseudophakic Bullous Keratopathy (PBK)**

Epithelial bullae or desquamation, degenerative  
pannus in late cases

Thickened edematous stroma (cotton candy  
appearance)

Posterior folds, loss of artifactual clefts in  
advanced cases

Descemet's membrane thin, no guttae

Several atrophy of endothelium

# Pseudophakic Bullous Keratopathy

epithelial bulla

stromal edema

Severe endothelial atrophy

Descemet's  
membrane  
normal

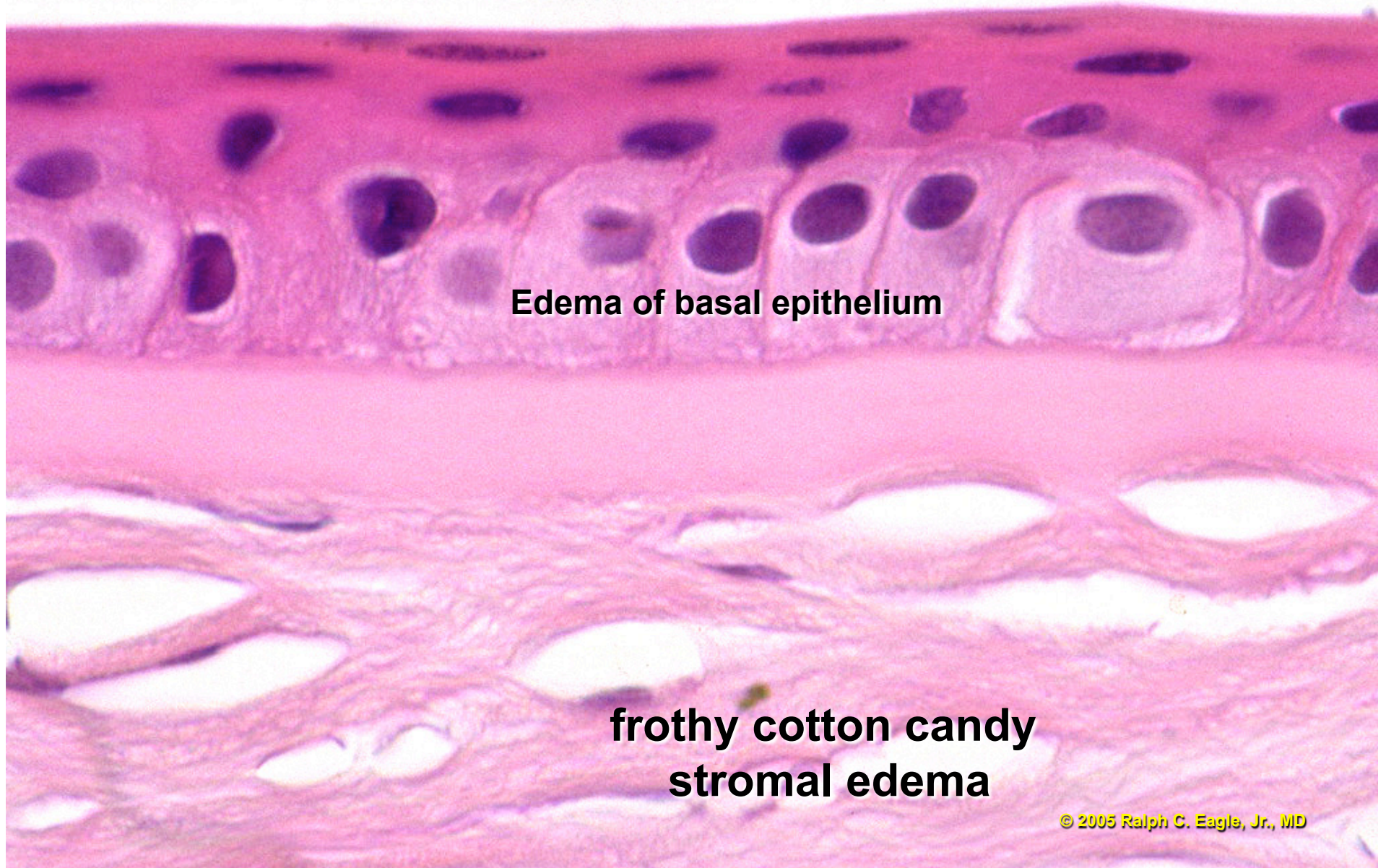# **Pseudophakic Bullous Keratopathy**

**frothy cotton candy  
stromal edema**

**Severe endothelial atrophy**

**Descemet's  
membrane  
normal**

# Pseudophakic Bullous Keratopathy



**Edema of basal epithelium**

**frothy cotton candy  
stromal edema**

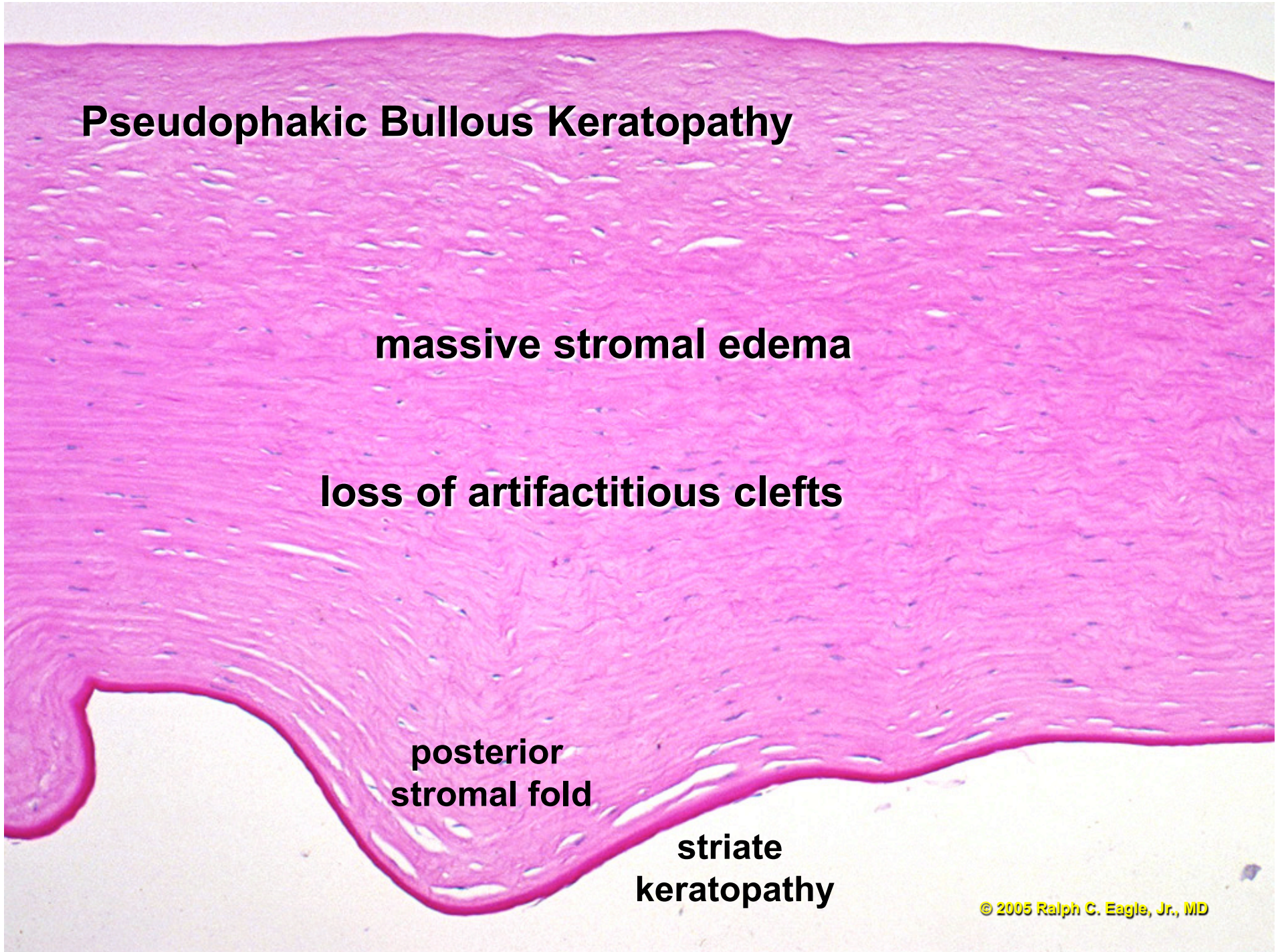
# **Pseudophakic Bullous Keratopathy**

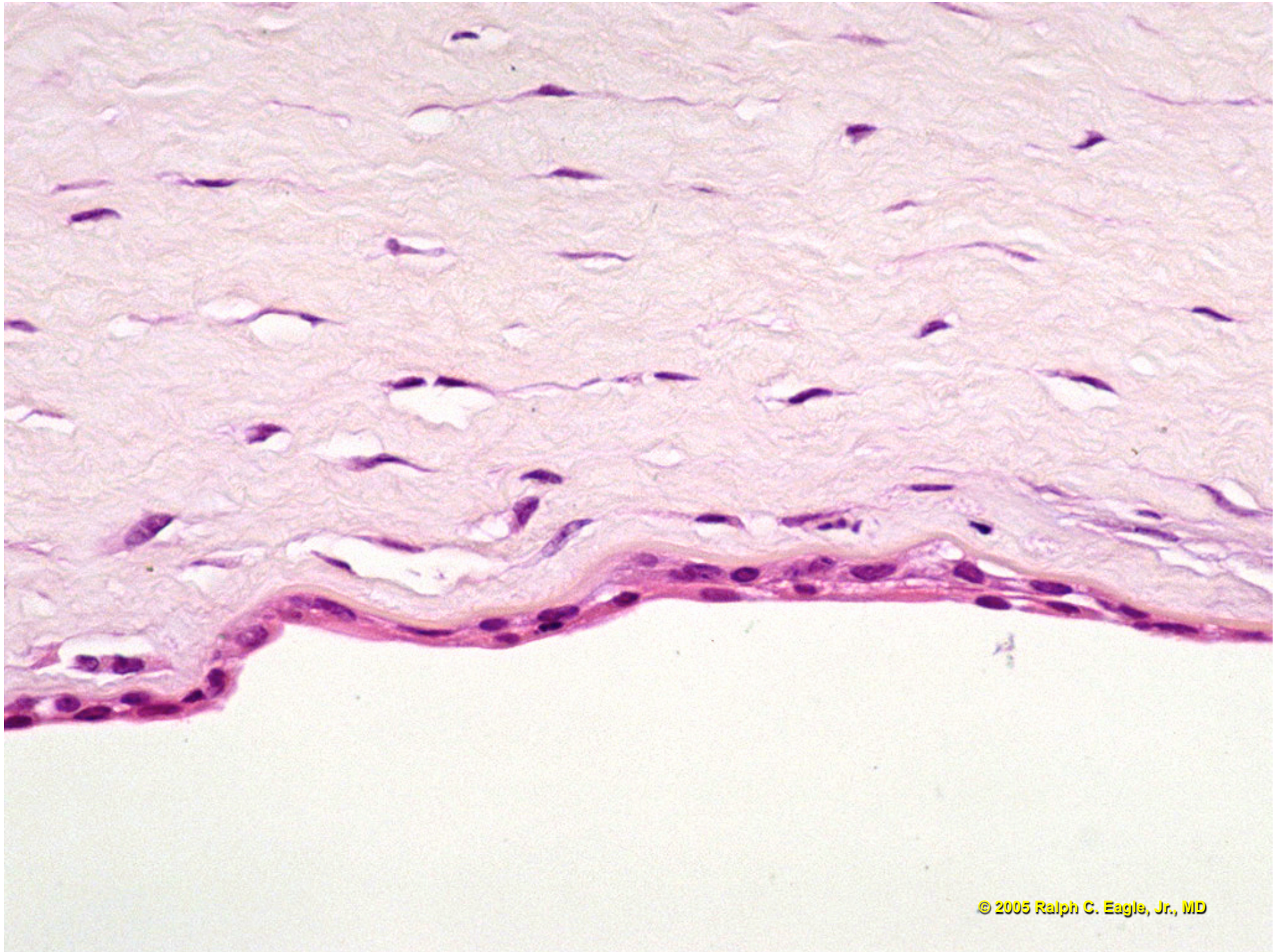
**massive stromal edema**

**loss of artifactitious clefts**

**posterior  
stromal fold**

**striate  
keratopathy**





# Posterior Polymorphous Dystrophy

Endothelial cells have epithelial characteristics:

Multilayered

Tonofilaments

Multiple microvilli

Express surface keratins

# Posterior Polymorphous Dystrophy

A histological micrograph showing a cross-section of the posterior polymorphous dystrophy. The image displays a thick, multilayered endothelium with a wavy, undulating surface. The endothelial cells are arranged in multiple layers, with some cells showing a more epithelial appearance. The underlying tissue is stained pink and purple, showing a dense network of fibers and cells.

multilayered endothelium

***endothelium has epithelial characteristics***